

**EAO**  
EUROPEAN ASSOCIATION  
FOR OSSEOINTEGRATION

JOINT MEETING  


  
German Association  
of Oral Implantology

# **BERLIN** **RELOADED** / **2023**

30<sup>th</sup> EAO annual scientific meeting  
37<sup>th</sup> DGI annual congress

**28-30 September 2023**

Congress  
**Scientific**  
Report



# Congress **Scientific** Report

## 30th EAO Annual Scientific Meeting Berlin, 28–30 September 2023

### Authored by the Congress Scientific Report Subcommittee 2023

#### Co-chairs:

Lino Esteve-Colomina  
Guillermo Esteve-Pardo

#### Members (Spain):

Javier Amigó-Bardají  
Pedro Barreiro-Gabeiras  
Ambrosio Bernabeu-Esclapez  
Ernesto DeLarriva-González

Alberto Salgado-Velázquez  
Luis Miguel Sánchez-Suárez  
Emilio Sánchez-Talaverano

With the support of the following team from the Goethe University in Frankfurt, Germany:

Ausra Ramanauskaite

Carla Schliephake  
Emilio Cafferata  
Ninad Padhye

This report provides a summary of 16 principal sessions which took place at the EAO's 30th Annual Scientific Meeting. The report was written by a group of delegates who have been preparing scientific reports on the EAO Congress since 2015. The EAO wishes to emphasise that this is not a peer-reviewed scientific

report. The contents do not necessarily represent the views of the EAO and readers are responsible for independently evaluating any information contained in the report. Nonetheless, the EAO hopes that the report will provide a useful and informative summary of the proceedings of its 30th Annual Scientific Meeting.



# Contents

<b>Acknowledgements</b> .....	<b>3</b>	<b>How to handle patients with stage IV periodontitis</b> .....	<b>32</b>
<b>Methodology</b> .....	<b>3</b>	How to handle patients with stage IV periodontitis: fixed restorations.....	32
<b>Copyright</b> .....	<b>3</b>	How to handle patients with stage IV periodontitis: removable restorations.....	34
<b>Treatment concepts anterior region: long-term aesthetics</b> .....	<b>4</b>	<b>The frail patient: how to include patient perspectives</b> .....	<b>36</b>
Parameters for long-term success of anterior single implants: the prosthodontist's point of view.....	4	Managing phonetics complications in implant dentistry.....	36
Replacing neighbouring anterior teeth: cantilever preferred?.....	6	Patient perspective.....	38
<b>Treatment concepts posterior region: long-term stability</b> .....	<b>8</b>	<b>Treatment concept in the posterior region: timing concepts</b> .....	<b>40</b>
Replacement of posterior teeth: implant vs conventional restorations.....	8	Immediate versus conventional implant placement in molar sites.....	40
Replacement of multiple posterior teeth with implants: cantilever preferred?.....	10	Immediate versus conventional loading of implants in the posterior region.....	43
<b>Peri-implant diseases reloaded: immune response, cellular cross-talk, microbiome</b> .....	<b>12</b>	<b>Treatment concepts posterior region: sinus lift reloaded</b> .....	<b>46</b>
Pathogenesis in peri-implantitis.....	12	Battle of concepts: lateral open sinus lift.....	46
The importance of the microbioma and probiotics in peri-implant disease.....	14	Battle of concepts: transalveolar/crestal sinus lift.....	48
Peri-implantitis: more than a bacterial infection.....	16	<b>The frail patient: how to reduce treatment morbidity</b> .....	<b>50</b>
Should implants be viewed like teeth or considered to be foreign bodies?.....	17	Partially dentate: implants or conventional restoration.....	50
<b>The frail patient: how to manage medical risk factors</b> .....	<b>18</b>	The edentulous frail patient: how to minimise invasiveness.....	52
Chronic diseases immunocompromised patients – focus on osteoporosis.....	18	<b>Big data and artificial intelligence: the future in implant dentistry</b> .....	<b>53</b>
The frail patient and antiresorptive agents.....	20	The future of digital data: an AI perspective to medicine.....	53
<b>Peri-implant diseases reloaded: choice of material and shape</b> .....	<b>22</b>	Digital implant dentistry reloaded: artificial intelligence in implant dentistry.....	55
The effect of abutment surface and abutment material on peri-implant health and diseases.....	22	Digital implant dentistry reloaded: big data in implant dentistry.....	57
The effect of the emergence profile on peri-implant health and diseases.....	24	<b>Battle of concepts: surgical treatment of peri-implantitis</b> .....	<b>59</b>
<b>The frail patient: how to manage physical and mental deterioration</b> .....	<b>27</b>	Peri-implantitis treatment: a stepwise approach.....	59
The frail patient: biological and functional decline.....	27	Reconstruction of peri-implantitis defects. The why, when and how ... in 15 minutes.....	61
Mental deterioration: prosthodontic concepts.....	29	Resective therapy for peri-implantitis.....	63
		<b>Interdisciplinary management of complex cases reloaded</b> .....	<b>65</b>

---

## Acknowledgements

The EAO would like to gratefully acknowledge the substantial work carried out by the Congress Scientific Report Subcommittee. The Board of Directors would also like to thank all chairs and speakers who have agreed to share their presentations.

## Methodology

The methodology underpinning this report is as follows:

1. A team of dentist delegates volunteered to write the report and arranged to attend all the sessions covered in it during the EAO's 2023 meeting in Berlin.
2. They provided a draft summary of each presentation to the EAO, which arranged for a copywriting team to edit it.
3. The editors returned the edited contributions to the authors highlighting any questions they had.
4. On receipt of responses to their questions, the editors updated the contributions, then forwarded them to each of the speakers featured, along with a request for a selection of their slides (selected by the authors).
5. Each speaker was contacted to request their feedback.

## Copyright

A number of speakers allowed a selection of their slides to be included in this report. Readers should be aware that copyright in any original content included in these slides remains the property of the speakers, and/or any other third-party copyright holders. These slides must not be circulated other than as part of this report, and should not be copied or reused without the express permission of the relevant speakers.



# Treatment concepts anterior region: long-term aesthetics

**Stefano Gracis**

## Parameters for long-term success of anterior single implants: the prosthodontist's point of view

The long-term success of implant treatment depends on a number of factors, including:

- appropriate patient selection
- having sufficient bone and soft tissue volume
- being able to place the implant in the optimal position
- the versatility of the implant system from the prosthetic point of view
- appropriate tissue management
- selection and application of the most reliable protocols
- the expertise of the dental technician

To achieve a correct three-dimensional placement of a dental implant, the following distances should be respected:

- mesio-distal distance between an implant and a tooth: 1.5 mm or greater
- thickness of the vestibular or palatal cortical bone: about 2mm
- distance between the implant platform and the gingival peri-implant mucosal margin: 4mm or greater

In addition, the more the implant axis is inclined to the buccal, the greater the tendency of the soft tissue margin to migrate apically.

The speaker described the soft tissue 'tunnel' between the implant platform at bone crest and the mucosal margin and explained how this can be divided in the subcritical contour and critical contour regions. Both have an impact on the final position of the gingiva<sup>1</sup>. The deeper subcritical contour of the abutments should be flat or concave, creating a space for the soft tissue in the buccal/lingual and interproximal areas. The critical contour, which is the most coronal portion, should instead have a convex profile to support and stabilise the soft tissue margin.

The gingival thickness must also be taken into account when considering the abutment. For gingival thicknesses greater than 3mm, titanium abutments can be used, but for thinner gingival thicknesses, zirconia abutments should be used<sup>2</sup>. In cases where the implant axis is too buccal, the need to modify the abutment to compensate it can make it significantly weakened. To avoid abutment fractures, the minimum wall thickness should be 0.7mm for a titanium abutment and 0.9mm for a zirconia one.

In terms of crown retention, cement-retained crowns are associated with improved aesthetics and better occlusal contacts since there are no holes interfering with the occlusion. On the other hand, there is a risk of cement residues that may cause peri-implantitis. By contrast, modern screw-retained prostheses use small diameter screws with correspondingly small access holes that have a minimal impact on aesthetics and occlusion.

When the vertical and horizontal position of the implant are incorrect and the patient does not wish to opt for implant removal, a two-piece approach can be considered, with one piece that restores the tissues with pink porcelain, and a cemented crown that restores the tooth.

Turning to the configuration of the implant-abutment interface, an internal connection and platform switching seems to be the preferred approach currently. However, not all internal connections are the same and it's important to differentiate between conical and flat-to-flat connections, and whether the system is self-locking or not.

Platform switching is often described as a configuration that improves bone and peri-implant soft tissue stability. However, many other confounding factors can influence the final tissue position.<sup>3</sup>

With regard to the prosthesis insertion protocol, it is still unclear whether repeated connection and disconnection of abutments leads to an increased risk of bone or soft tissue loss. One-time abutments show less vertical change in bone and soft tissue, but the difference is of slight clinical significance. There are several confounding factors to consider, such as immediate versus delayed implant placement, crestal versus subcrestal positioning, soft tissue phenotype, and type of prosthesis retention (screw versus cement).

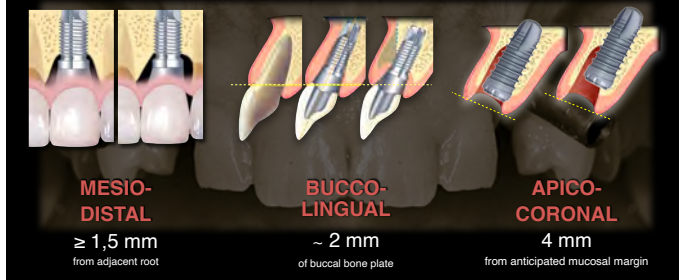
The speaker concluded by summarising all the variables that can affect the long-term success of single-tooth anterior implants, emphasising that the position of the implant is the most important factor, because that is where it all starts. He also made the point that, if it is not possible to change the conditions in order to place an implant in an optimal position, a minimally-invasive tooth supported fixed dental prosthesis should be considered.

1. Su H, Gonzalez-Martin O, Weisgold A, Lee E. Considerations of implant abutment and crown contour: critical contour and subcritical contour. *Int J Periodontics Restorative Dent.* 2010;30(4):335-43.

2. Jung RE, Sailer I, Hämmerle CH, Attin T, Schmidlin P. In vitro color changes of soft tissues caused by restorative materials. *Int J Periodontics Restorative Dent.* 2007;27(3):251-7.

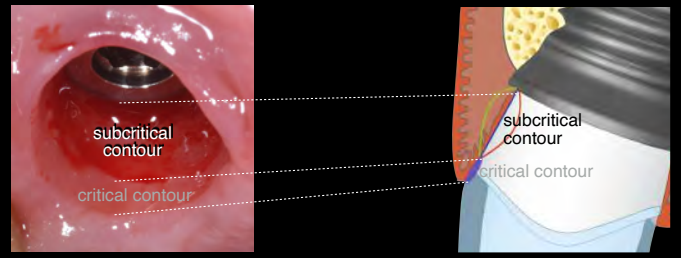
3. Juan-Montesinos A, Agustín-Panadero R, Solá-Ruiz MF, Marco-Pitarch R, Montiel-Company JM, Fons-Badal C. Comparative study by systematic review and meta-analysis of the peri-implant effect of two types of platforms: platform-switching versus conventional platforms. *J Clin Med.* 2022;21;11(6):1743. DOI:10.3390/jcm11061743.

## 1. 3-D implant position



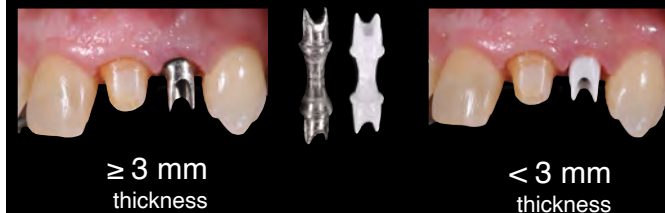### SUBCRITICAL CONTOUR

- ❖ Apical to the critical contour, whenever the tunnel is deep enough
- ❖ Can be concave, flat or convex
- ❖ Overcontouring on facial beyond physiologic tolerance may cause recession
- ❖ Convex interproximal profiles may squeeze the papilla to push it coronally, provided there is enough interdental space (2-3 mm) and matured tissue



## INDICATIONS for WHITE ABUTMENTS

The abutment material influences the color that shows through the tissues



Jung RE, Sailer I, Hammerle CH, Attin T, Schmidlin P  
In vitro color changes of soft tissues caused by restorative materials.  
*Int J Periodontics Restorative Dent* 2007;27:251-7



## Requirements for long-term success of anterior single implants

### IMPLANT POSITION AND PROFILES

- ▶ Proper hard and soft tissue volume
- ▶ Thick tissue phenotype
- ▶ Exact 3-D placement (guided surgery?), prosthetically driven
- ▶ Whenever possible, B-L position compatible with screw-retained restoration
- ▶ Crown or abutment contour which "supports" periimplant mucosa

### IMPLANT-ABUTMENT CONFIGURATION

- ▶ There is no optimal abutment connection configuration, but internal connections may be preferable
- ▶ Appropriate torque for abutment screw stability
- ▶ Platform switching?

### PROSTHESIS INSERTION PROTOCOL

- ▶ Whenever possible, avoidance of repeated abutment disconnections and reconnections
- ▶ Abutment-level restoration advantageous over implant-level in bone-level implants

## Henny Meijer

### Replacing neighbouring anterior teeth: cantilever preferred?

The speaker presented a recently published case series in which two implants were placed to restore two neighbouring missing anterior teeth<sup>1</sup>. The series included 10-year results for 17 patients. Although papilla index scores were below the maximum between an implant and a tooth, and significantly below the maximum between two implants, patients expressed high levels of satisfaction with their treatment and the final aesthetic aspect. The speaker concluded that although it is difficult to obtain sufficient inter-implant papillae, the initial results remained stable over time, and patients were satisfied with the results.

A recent systematic review featuring nine articles, comprising 11 study groups, included 10-year results of a prospective pilot study comparing two treatment options: two implants supporting two single crowns or one implant with an implant-cantilever crown. Implant survival, marginal bone and soft tissue changes were similar for both treatment options<sup>2</sup>.

There were some technical complications, such as screw loosening or chipping, but surprisingly these were not significant between the two groups. A recent in vitro study has shown that even when using a cantilevered zirconia framework, it is strong

enough to withstand occlusal forces without fracturing, providing it is in the anterior region<sup>3</sup>.

The speaker then presented a case that involved immediate implant placement after extraction of the two central incisors. Following placement of the definitive restorations, he noted that although there may be a slight loss of papilla height, the results could be expected to remain stable for at least 10 years. Guidelines for implant treatment in cases featuring two failing or missing central incisors recommend that if there is an existing bone defect, alveolar ridge preservation should be performed followed by placement of implants, plus provisionals, after 3 months<sup>4</sup>.

In conclusion, although there is limited literature on replacing two neighbouring teeth in the aesthetic zone and it is difficult to obtain sufficient inter-implant papillae and satisfactory Pink Esthetic Scores, initial treatment results remain stable and patients are satisfied with the final result over a 10-year follow-up period. Furthermore, a single implant-supported cantilever crown can be a viable alternative to placing two adjacent single implant crowns in the aesthetic zone.

#### Systematic review

To summarize:

	Implant-Cantilever	Implant-Implant
Implant survival	96.9%	97.6%
Marginal bone level changes	limited	limited
Presence of papillae	compromised	compromised
Objective aesthetics	hardly reported	hardly reported
Patient satisfaction	highly satisfied	highly satisfied

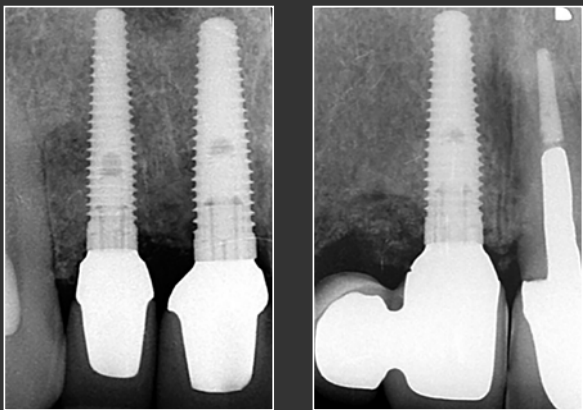


University Medical Center Groningen

- Meijer HJA, Stellingsma K, Vissink A, Raghoobar GM. *Two adjacent implant-supported restorations in the aesthetic region: A 10-year prospective case series*. Clin Implant Dent Relat Res. 2023 Sep 5. DOI:10.1111/cid.13274.
- Meijer HJA, Stellingsma K, Pol CWP, Vissink A, Gareb B, Raghoobar GM. *Dental implant treatment for two adjacent missing teeth in the esthetic region: A systematic review and 10-year results of a prospective comparative pilot study*. Clin Exp Dent Res. 2023 Aug 17. DOI:10.1002/cre2.773.
- Karasan D, Canay S, Sailer I, Att W. *Zirconia Cantilever Fixed Dental Prostheses Supported by One or Two Implants: An In Vitro Study on Mechanical Stability and Technical Outcomes*. Int J Oral Maxillofac Implants. 2022;37(4):748-55. DOI:10.11607/jomi.8953.
- van Nimwegen WG, Raghoobar GM, Vissink A, Meijer HJA. *Implant treatment of two failing or missing central incisors in the aesthetic region: a treatment protocol and 1-year prospective study*. Int J Oral Maxillofac Surg. 2019;48(8):1115-21. DOI:10.1016/j.ijom.2019.01.005.

10-year follow-up of one implant with a crown and cantilever

Two groups



University Medical Center Groningen

10-year follow-up of one implant with a crown and cantilever

Papilla index

	Implant-Cantilever			Implant-Implant		
	Central tooth-implant	Implant-cantilever	Cantilever-cuspid	Central tooth-implant	Implant-implant	Implant-cuspid
Score 0	0	0	0	0	0	0
Score 1	1	5	1	1	3	1
Score 2	2	0	2	4	2	1
Score 3	2	0	2	0	0	3
Score 4	0	0	0	0	0	0

University Medical Center Groningen



# Treatment concepts posterior region: long-term stability

**Anja Zembic**

## Replacement of posterior teeth: implant vs conventional restorations

The literature emphasizes that dental implants are the preferred treatment for single-tooth replacements due to their superior long-term survival rates compared to conventional fixed prostheses.

Apart from the survival rates, patient satisfaction is a key factor for the achievement of a successful treatment outcome. While patients tend to prefer fixed prostheses over removable ones, no difference in patient satisfaction was found between resin-bonded bridges<sup>1</sup> and implants.

There are inherent aesthetic, technical, and biological risks associated with placing implants. The latter two are of specific importance in the posterior region. Changes in the craniofacial structure can affect implant success over time. Resin-bonded bridges are less sensitive to this<sup>2</sup> phenomenon since they follow the tooth movement in contrast to the ankylotic bone anchorage of an implant. Systematic reviews suggest similar survival rates for both implants and fixed prostheses at 5 and 10<sup>3,4</sup> years, with resin-bonded bridges lagging slightly behind at ten years. A case-control study found similar survival rates at 9.5 years for implant-supported crowns and resin-bonded bridges, with a higher success rate and fewer biological complications for resin-bonded bridges<sup>5</sup>. In this context, a higher success rate means the restorations did not only stay in the mouth, but were more likely to be free of complications. Tooth preparation is one of the key factors for resin-bonded bridges with no preparation being preferable.<sup>6</sup> With regard

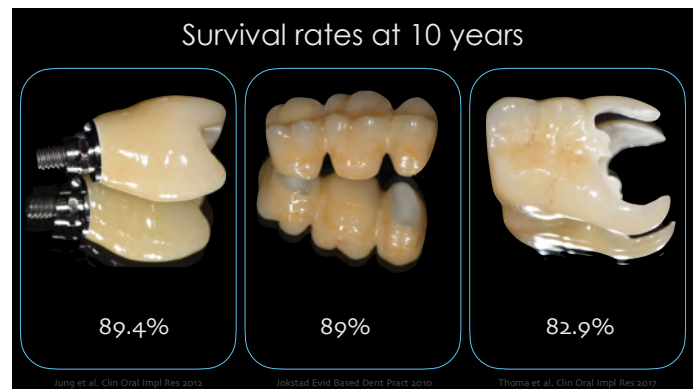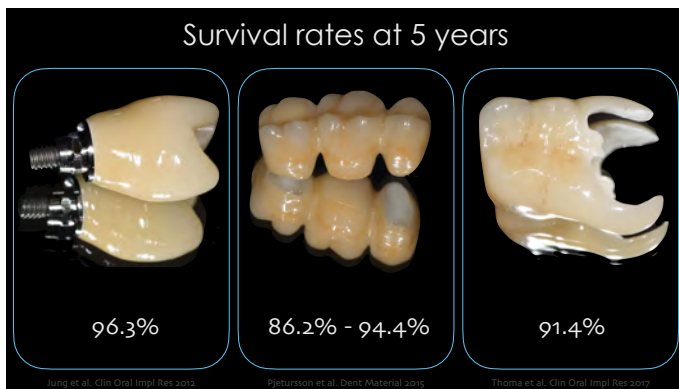to the design, one retainer with two wings and occlusal rest is suggested and results in significantly<sup>7</sup> higher bond strength in vitro.

There is no scientific evidence on the suggested location of the pontic (mesial or distal). Based on the finding that the highest stress occurs within the connector and on the gingival area of the pontic<sup>8</sup>, along with the natural drift of teeth, which tend to move more mesially than distally regardless of<sup>9</sup> age, the pontic should probably be mesial in such restorations.

Resin-bonded bridges offer several advantages compared with implants, including minimal invasiveness at low costs. They are an appropriate treatment option for several patient groups, such as patients with dental anxiety, economic limitations or medical issues that contraindicate surgery. Successful treatment outcomes depend on the clinician's experience and clinical skills, but also on<sup>10</sup> using the correct adhesive cementation protocol.

Individual patient factors and anatomical considerations play a crucial role in determining the best treatment option. Dental professionals should carefully assess each situation individually and inform the patient on survival rates and pros and cons of different treatment options to help the patient with the decision and ensure long-term patient satisfaction.

- 1 Creugers NH, De Kanter RJ. *Patients' satisfaction in two long-term clinical studies on resin-bonded bridges*. J Oral Rehabil. 2000;27(7):602-7. DOI:10.1046/j.1365-2842.2000.00553.x.
- Lam WY, Botelho MG, McGrath CP. *Longevity of implant crowns and 2-unit cantilevered resin-bonded bridges*. Clin Oral Implants Res. 2013;24(12):1369-74. DOI:10.1111/clr.12034.
- 2 Papageorgiou SN, Eliades T, Hämmeler CHF. *Frequency of infraposition and missing contact points in implant-supported restorations within natural dentitions over time: A systematic review with meta-analysis*. Clin Oral Implants Res. 2018;29 Suppl 18:309-25. DOI:10.1111/clr.13291.
- 3 Jung RE, Zembic A, Pjetursson BE, Zwahlen M, Thoma DS. *Systematic review of the survival rate and the incidence of biological, technical, and aesthetic complications of single crowns on implants reported in longitudinal studies with a mean follow-up of 5 years*. Clin Oral Implants Res. 2012;23 Suppl 6:2-21. DOI:10.1111/j.1600-0501.2012.02547.x
- Pjetursson BE, Sailer I, Makarov NA, Zwahlen M, Thoma DS. *All-ceramic or metal-ceramic tooth-supported fixed dental prostheses (FDPs) A systematic review of the survival and complication rates. Part II: Multiple-unit FDPs*. Dent Mater. 2015;31(6):624-39. DOI:10.1016/j.dental.2015.02.013.
- 4 Thoma DS, Sailer I, Ioannidis A, Zwahlen M, Makarov N, Pjetursson BE. *A systematic review of the survival and complication rates of resin-bonded fixed dental prostheses after a mean observation period of at least 5 years*. Clin Oral Implants Res. 2017;28(11):1421-32. DOI:10.1111/clr.13007.
- Jokstad A. *After 10 years seven out of ten fixed dental prostheses (FDP) remain intact and nine out of ten FDPs remain in function following biological and technical complications that have been repaired*. J Evid Based Dent Pract. 2010;10(1):39-40. DOI:10.1016/j.jebdp.2009.11.019.
- 5 Lam WY et al. 2013. Opus cit.
- 6 Edelhoff D, Sorensen JA. *Tooth structure removal associated with various preparation designs for anterior teeth*. J Prosthet Dent. 2002;87(5):503-9. DOI:10.1067/mpr.2002.124094.
- King PA, Foster LV, Yates RJ, Newcombe RG, Garrett MJ. *Survival characteristics of 771 resin-retained bridges provided at a UK dental teaching hospital*. Br Dent J. 2015;218(7):423-8. DOI:10.1038/sj.bdj.2015.250.
- 7 Tagami A, Chaar MS, Wille S, Tagami J, Kern M. *Retention of posterior resin bonded fixed dental prostheses with different designs after chewing simulation*. J Mech Behav Biomed Mater. 2021;123:104758. DOI:10.1016/j.jmbbm.2021.104758.
- 8 Kelly JR, Tesk JA, Sorensen JA. *Failure of all-ceramic fixed partial dentures in vitro and in vivo: analysis and modeling*. J Dent Res. 1995;74(6):1253-8. DOI:10.1177/00220345950740060301.
- 9 Bhai K, Judge R, Abdou J, Palamara J. *Measuring tooth movement with treatment using the Dahl principle: An observational study*. J Prosthet Dent. 2023;129(4):554-60. DOI:10.1016/j.prosdent.2021.07.010
- 10 King PA, et al. 2015. Opus cit.



### Pros for RBB

- Minimally invasive, reversible treatment option
- No risk of pulp irritation
- Minimal caries risk
- Reduced gap size
- No anesthesia, no surgery, no bone grafting - less morbidity
- Low costs
- Short treatment time
- Metall-free
- Ideal treatment for young patients, the elderly, patients with dental phobia

### Longevity ISC vs. RBB

- Similar survival rates at 9.5 years
- Higher success rate for RBBs
- Less biological complications for RBBs

Lam, Botelho, McGrath Clin Oral Impl Res 2013 (case control study)

### Key factors for RBB

- Tooth preparation
- Design
- Framework material
- Location
- Clinician's experience

Thoma et al. Clin Oral Impl Res 2017; King et al. Brit Dent J 2015; Sailer et al. Int J Prosthodont 2013

### Summary

- ✓ RBB viable treatment option for the posterior
- ✓ Minimal / no preparation confined to enamel
- ✓ Bonding surface  $\geq 30\text{mm}^2$
- ✓ Zirconia as framework material
- ✓ Adhesive cementation
- ✓ Good oral hygiene & regular maintenance crucial

## Vincent Donker

### Replacement of multiple posterior teeth with implants: cantilever preferred?

The speaker focused on cantilever implant-supported fixed dental prostheses, which are a treatment option in cases where multiple posterior teeth need to be replaced using the fewest possible implants. These prostheses offer advantages such as reduced surgical time, morbidity and costs, thereby promoting minimally invasive dentistry. Several critical factors that influence this type of treatment were discussed, including considerations relating to the patient, the implant and the prosthesis<sup>1</sup>.

Regarding the patient, anatomical and economic considerations that affect the implant treatment plan were discussed, with the recognition that the patient's financial limitations may influence the decision to opt for a cantilever prosthesis if they cannot afford two implants<sup>2</sup>.

A cantilever implant-supported fixed dental prosthesis is also indicated when there is inadequate volume of available bone, or there is insufficient space to place two implants. Critical anatomical considerations in the posterior region were also discussed which could justify the choice of a cantilever prostheses as an alternative to placing additional implants or carrying out a more complex procedure, such as a sinus lift.

Implant-related factors were also addressed, such as the implant type, diameter, and length. There are a limited number of studies comparing different implant designs for cantilever prostheses,

although the literature suggests that implants should have a diameter of at least 4 mm and a length of at least 8 mm to withstand potential overloading of the implant in this type of restoration<sup>3</sup>.

Screw-retained internal conical connections are considered preferable in order to minimise screw loosening, as well as being easier to remove should any complications of the prosthesis occur<sup>4</sup>.

Looking at the prosthesis itself, there are no differences in survival rates between cantilever prostheses with mesial or distal extensions, although technical complications are more frequent with distal extensions<sup>5</sup>. Laboratory and clinical studies have determined that a single implant can support a prosthesis of up to 13 mm in height and up to 16 mm wide, although cantilever extensions should not exceed 8 mm. The choice of the restorative material was mentioned, with the use of zirconia potentially beneficial for reducing ceramic chipping<sup>6</sup>. In certain cases, a CAD-CAM abutment can reduce the angle between the implant and the prosthesis, possibly reducing the risk of screw fracture or loosening<sup>7</sup>.

The speaker also addressed the success rate and complications associated with cantilever prostheses. He presented an analysis of systematic reviews published in the last 15 years on cantilever implant-supported fixed dental prostheses. Under 'complicating factors', he noted that group function and parafunctional tendencies can contribute to prosthetic failure, along with

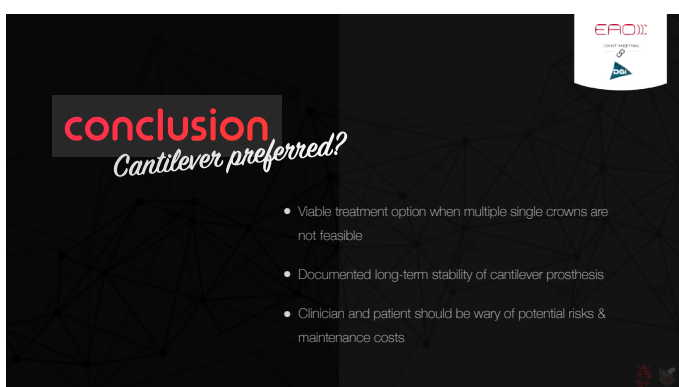
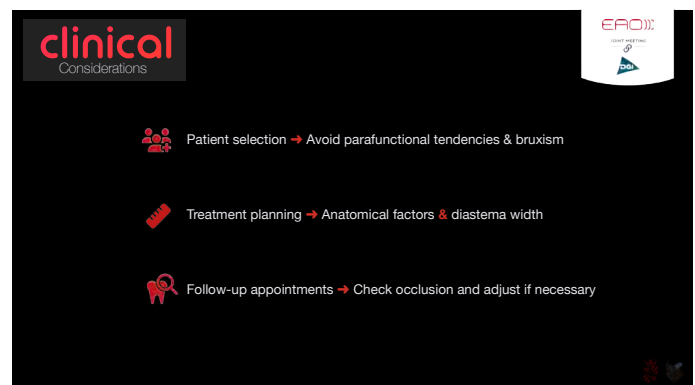
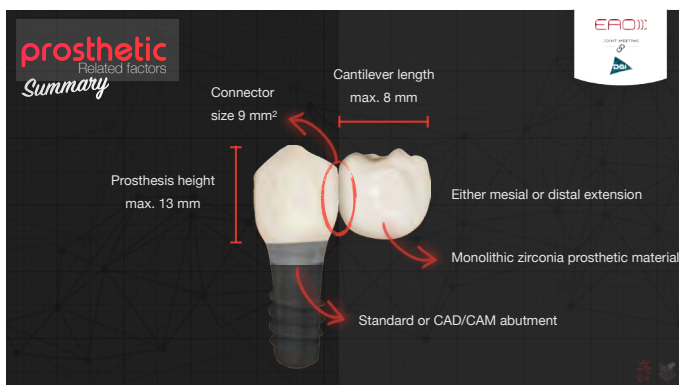
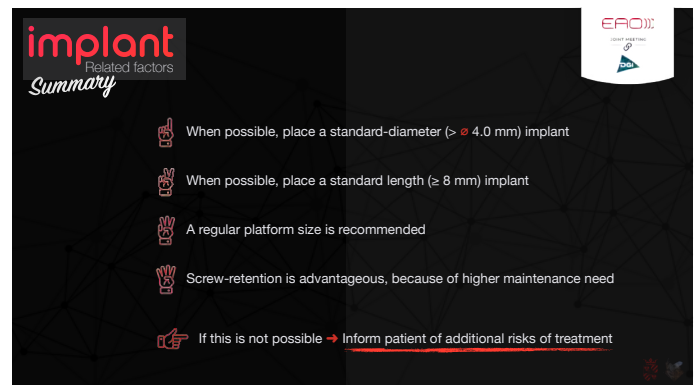
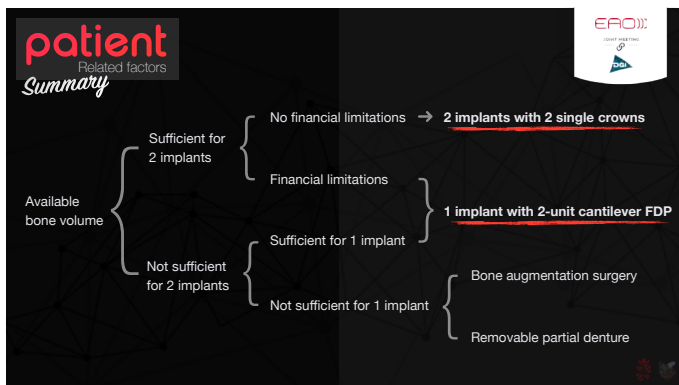
- 1 Gallucci GO, Avramopou M, Taylor JC, Elpers J, Thalji G, Cooper LF. *Maxillary Implant-Supported Fixed Prosthesis: A Survey of Reviews and Key Variables for Treatment Planning*. Int J Oral Maxillofac Implants. 2016;31 Suppl:s192-7. DOI:10.11607/jomi.16suppl.g5.3. Aglietta M, Iorio Siciliano V, Blasi A, Sculean A, Bragger U, Lang NP, Salvi GE. *Clinical and radiographic changes at implants supporting single-unit crowns (SCs) and fixed dental prostheses (FDPs) with one cantilever extension. A retrospective study*. Clin Oral Implants Res. 2012;23(5):550-5. DOI:10.1111/j.1600-0501.2011.02391.x.
- 2 Rocuzzo A, Fanti R, Mancini L, Imber JC, Stähli A, Molinero-Mourelle P, Schimmel M, Sculean A, Salvi GE. *Implant-supported fixed dental prostheses with cantilever extensions: State of the art and future perspectives*. Int J Oral Implantol (Berl). 2023;16(1):13-28. PMID: 36861678.
- 3 Palmer RM, Howe LC, Palmer PJ, Wilson R. *A prospective clinical trial of single Astra Tech 4.0 or 5.0 diameter implants used to support two-unit cantilever bridges: results after 3 years*. Clin Oral Implants Res. 2012;23(1):35-40. DOI:10.1111/j.1600-0501.2011.02160.x. Jung RE, Al-Nawas B, Araujo M, et al. *Group 1 ITI Consensus Report: The influence of implant length and design and medications on clinical and patient-reported outcomes*. Clin Oral Implants Res. 2018;29 Suppl 16:69-77. DOI:10.1111/clr.13342. Zumstein K, Waller T, Hämmerle CHF, Jung RE, Benic G, Mühlemann S. *Clinical performance of monolithic zirconia crowns on titanium-zirconium reduced-diameter implants in the molar area: Interim data at three years of a randomized controlled trial*. Clin Oral Implants Res. 2023 Sep 5. DOI:10.1111/clr.14179. Storelli S, Del Fabbro M, Scanferla M, Palandrani G, Romeo E. *Implant supported cantilevered fixed dental rehabilitations in partially edentulous patients: Systematic review of the literature. Part I*. Clin Oral Implants Res. 2018;29 Suppl 18:253-74. DOI:10.1111/clr.13311. Thoma DS, Wolleb K, Schellenberg R, Strauss FJ, Hämmerle CHF, Jung RE. *Two short implants versus one short implant with a cantilever: 5-Year results of a randomized clinical trial*. J Clin Periodontol. 2021;48(11):1480-90. DOI:10.1111/jcpe.13541.
- 4 Romanos GE, Gupta B, Eckert SE. *Distal cantilevers and implant dentistry*. Int J Oral Maxillofac Implants. 2012;27(5):1131-6. PMID: 23057026. Coray R, Zeltner M, Özcan M. *Fracture strength of implant abutments after fatigue testing: A systematic review and a meta-analysis*. J Mech Behav Biomed Mater. 2016;62:333-46. DOI:10.1016/j.jmbm.2016.05.011. Vinhas AS, Aroso C, Salazar F, López-Jarana P, Rios-Santos JV, Herrero-Climent M. *Review of the Mechanical Behavior of Different Implant-Abutment Connections*. Int J Environ Res Public Health. 2020 23;17(22):8685. DOI:10.3390/ijerph17228685.
- 5 Palmer RM, et al. 2012. Opus cit. Romeo E, Tomasi C, Finini I, Casentini P, Lops D. *Implant-supported fixed cantilever prosthesis in partially edentulous jaws: a cohort prospective study*. Clin Oral Implants Res. 2009;20(11):1278-85. DOI:10.1111/j.1600-0501.2009.01766.x.
- 6 Kim P, Ivanovski S, Latham N, Mattheos N. *The impact of cantilevers on biological and technical success outcomes of implant-supported fixed partial dentures. A retrospective cohort study*. Clin Oral Implants Res. 2014;25(2):175-84. DOI:10.1111/clr.12102. Alshahrani FA, Yilmaz B, Seidt JD, McGlumphy EA, Brantley WA. *A load-to-fracture and strain analysis of monolithic zirconia cantilevered frameworks*. J Prosthet Dent. 2017;118(6):752-8. DOI:10.1016/j.prodent.2017.01.028.
- 7 Wiskott HW, Jaquet R, Scherrer SS, Belser UC. *Resistance of internal-connection implant connectors under rotational fatigue loading*. Int J Oral Maxillofac Implants. 2007;22(2):249-57. PMID: 17465350. Lops D, Romeo E, Mensi M, Troiano G, Zhuravskaya K, Del Fabbro M, Palazzolo A. *CAD/CAM Abutments in the Esthetic Zone: A Systematic Review and Meta-Analysis of Soft Tissue Stability*. J Clin Med. 2023;12(11):3847. DOI:10.3390/jcm12113847. Târtea DA, Ionescu M, Manolea HO, Mercuț V, Obădan E, Amărăscu MO, Mărășescu PC, Dăguți L, Popescu SM. *Comparative Study of Dental Custom CAD-CAM Implant Abutments and Dental Implant Stock Abutments*. J Clin Med. 2021;10(6):2128. DOI:10.3390/jcm10062128.

premature occlusal contact on the cantilever extension. The opposing dentition should also be carefully examined, particularly if there is an opposing implant, as this can easily lead to overloading of the cantilever construction. The need for ongoing monitoring and adjustment of the prosthesis during patient follow-up was highlighted, along with a need for well-conducted prospective studies to provide a stronger evidence-base for best practice<sup>8</sup>.

While there is still a lot to be learned regarding cantilever restorations, there are also some techniques that can be harnessed already. For example, leveraging digital workflows leads to faster working times and reduced discomfort for the patient. The

speaker shared a digital workflow that combined immediate implant placement with immediate provisionalisation, followed by placement of a definitive monolithic zirconia prosthesis.

In summary, cantilever implant-supported fixed dental prostheses are a viable option when it is not possible to place two implants due to anatomical or economic limitations. However, a note of caution is required due to the possibility of increased risks and greater maintenance costs. Selecting suitable implants and abutments, combined with careful treatment planning, is essential for the success of these prostheses.



<sup>8</sup> Kadkhodazadeh M, Amid R, Moschowich A, Lakmazaheri E. Short-term and long-term success and survival rates of implants supporting single-unit and multiunit fixed prostheses: A systematic review and meta-analysis. J Prosthet Dent. 2023:S0022-3913(23)00008-2. DOI:10.1016/j.prosdent.2022.12.012.



# Peri-implant diseases reloaded: immune response, cellular cross-talk, microbiome

This session focused on the complex pathogenesis of peri-implantitis, many aspects of which are still unknown. If the causal factors were better understood, the prognosis could be improved as treatment strategies could be more focused, with a greater likelihood of success. The speakers presented new data that helped shed light on a number of key questions:

- Is there a signature, either microbiotic or proteomic, that allows a diagnosis of peri-implantitis?
- If dysbiosis reflect the progression of peri-implant disease, might probiotics provoke a shift in the microbiome?
- What is the cellular landscape in peri-implantitis, and what cellular cross-talk takes place?

## Tobias Fretwurst

### Pathogenesis in peri-implantitis

The pathogenesis of peri-implantitis is complex. As well as bacteria, foreign body giant cells and other immune cells can be found adjacent to implants, together with wear particles<sup>1</sup>. The speaker used an analogy of a coffee machine, noting that each device has a specific bacteriome<sup>2</sup>. This is similar to the varying peri-implant microbiomes that are found in different peri-implantitis patients<sup>3</sup>, making it impossible to use specific species to diagnose peri-implantitis. This is because the microbiome is non-specific and varies from patient to patient.

In one study looking at biopsies of peri-implant tissue collected when hopeless implants were removed in 15 patients, the authors concluded that histological differences were patient-specific (there was also no difference in immune cellularity between titanium and zirconia)<sup>4</sup>. In practice, immune cells are influenced by inter-individual differences that reflect the immune status of each individual patient.

Recent research in the emerging field of proteomic dentistry has led to important findings that have the potential to transform the diagnosis and treatment of peri-implant disease. Central to these advances is the detailed analysis of gingival crevicular fluid (GCF), a medium that harbours a spectrum of proteins that are indicative of physiological and pathological states within the oral environment.<sup>5,6</sup>

Using mass spectrometry and advanced data analysis techniques, researchers have identified several proteins in the GCF and correlated certain protein clusters with peri-implant health conditions. These clusters, or protein patterns, represent an

underlying biological response that manifests differently in healthy tissue compared to tissue affected by peri-implant disease.

Notably, despite inter-individual variability, there are consistent trends in protein expression that suggest common pathways that are activated or suppressed in response to peri-implant disease. These protein 'signatures' provide a set of potential biomarkers that could revolutionise diagnostic accuracy in dental practice.

The identification of unique protein profiles underlines the inadequacy of standard treatment strategies and highlights the need for personalised therapeutic approaches. By tailoring interventions to the individual proteomic characteristics of each patient, clinicians could more effectively address the specific causes and manifestations of peri-implant disease.

These protein biomarkers also have significant implication for long-term follow-up, providing clinicians with a valuable tool to monitor disease progression, assess responses to treatment and adjust therapeutic strategies as needed.

In conclusion, advances in proteomic analysis of gingival crevicular fluid are the first steps towards an era of personalised diagnosis and treatment in implant dentistry. Identifying each patient's unique protein profile will enable dental professionals to provide more accurate, effective and personalised treatment, thereby improving clinical outcomes and quality of life for patients with peri-implant disease.

1 Fretwurst T, Nelson K, Tarnow DP, Wang HL, Giannobile WV. Is Metal Particle Release Associated with Peri-implant Bone Destruction? An Emerging Concept. J Dent Res. 2018;97(3):259-65. DOI:10.1177/0022034517740560

2 Vilanova C, Iglesias A, Porcar M. The coffee-machine bacteriome: biodiversity and colonisation of the wasted coffee tray leach. Sci Rep. 2015;23(5):17163. DOI:10.1038/srep17163

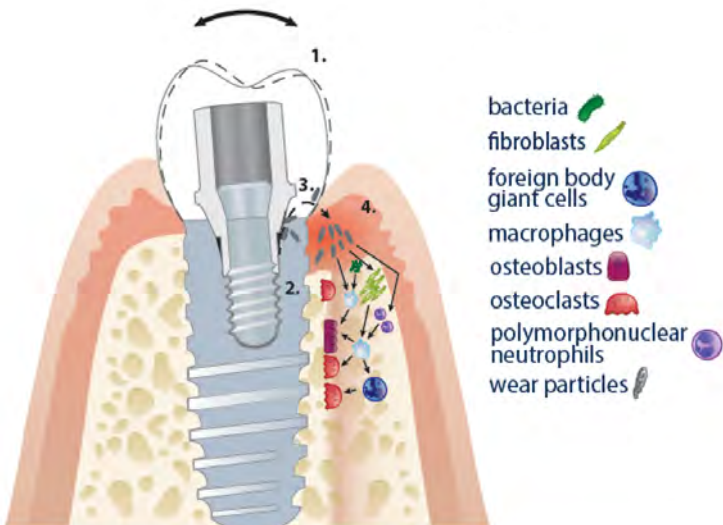
3 Dabdoub SM, Tsigarida AA, Kumar PS. Patient-specific analysis of periodontal and peri-implant microbiomes. J Dent Res. 2013;92(12 Suppl):168S-75S. DOI:10.1177/0022034513504950

4 Fretwurst T, Müller J, Larsson L, et al. Immunohistological composition of peri-implantitis affected tissue around ceramic implants-A pilot study. J Periodontol. 2021;92(4):571-9. DOI:10.1002/JPER.20-0169

5 Halstenbach T, Nelson K, Iglhaut G, Schilling O, Fretwurst T. Impact of peri-implantitis on the proteome biology of crevicular fluid: A pilot study. J Periodontol. 2023 Jul;94(7):835-847. doi: 10.1002/JPER.22-0461. Epub 2023 Feb 1. PMID: 36585920.

6 Halstenbach T, Topitsch A, Schilling O, Iglhaut G, Nelson K, Fretwurst T. Mass Spectrometry-Based Proteomic Applications in Dental Implants Research. Proteomics – Clinical Application 2024. In press. DOI: 10.1002/prca.202300019

Complexity

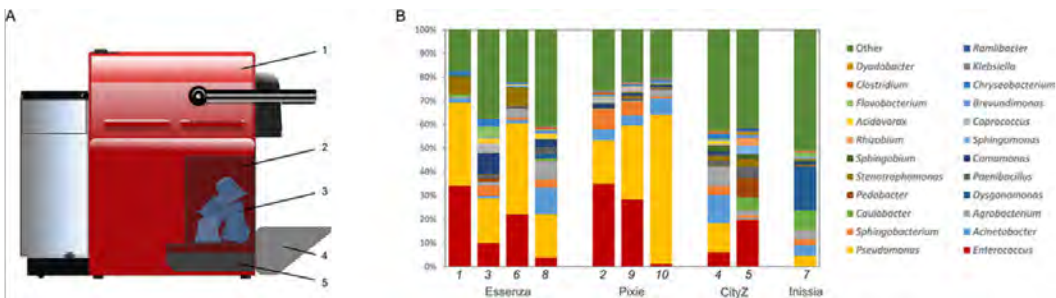


Mod. nach  
Fretwurst, Nelson,  
Tarnow, Giannobile  
JDR 2018

SCIENTIFIC REPORTS

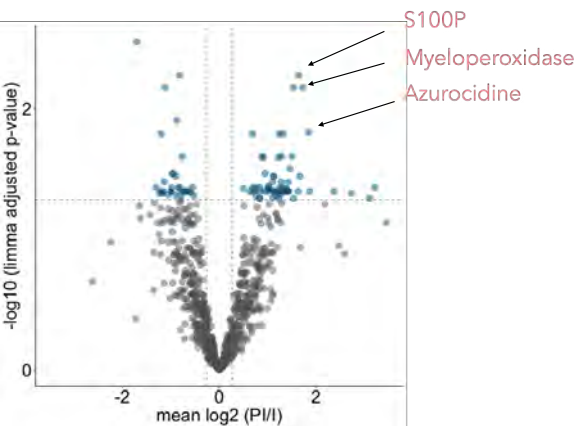
OPEN The coffee-machine bacteriome: biodiversity and colonisation of the wasted coffee tray leach

Received: 12 June 2015  
Accepted: 16 October 2015  
Cristina Vilanova<sup>1</sup>, Alba Iglesias<sup>1</sup> & Manuel Porcar<sup>1,2</sup>



Proteomics

Healthy Peri-implantitis



Halstenbach T, Nelson K,  
Iglhaut G, Schilling O,  
Fretwurst T - JOP 2023

## Daniel Jönsson

# The importance of the microbioma and probiotics in peri-implant disease

Five-year success rates in treating peri-implantitis have been shown to range from 56%<sup>1</sup> to 63%<sup>2</sup>. However, peri-implantitis can be very variable clinically. In simple cases, good results can be achieved, but there are also difficult cases where it will only be possible to slow the disease progression and reduce the inflammatory burden.

It is well recognised that bacteria and immunological reactions play a central role in the complex pathogenesis of peri-implantitis. Because studying the microbiome requires such large cohorts (more than 2,000 individuals) most studies have an insufficient sample size to reveal the strength of the associations<sup>3</sup>. This is the case in peri-implantitis patients. However, using metagenomic sequencing, one study claimed to have found microbiome signatures for peri-implantitis, identifying bacteria that are not present in patients with healthy peri-implant tissue<sup>4</sup>. Although a meta-analysis cannot replace a significant cohort study, a recent study that included 1,513 implants showed an association between *S. epidermidis*, specific periodontal pathogens, and peri-implantitis<sup>5</sup>. The findings raise the question of whether these species are included in the 'pocket microbiota'.

A study of over 100 implants concluded that implant surface topography modifies the associated microbiome and may influence the pathogenesis of peri-implantitis<sup>6</sup>.

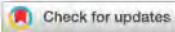
Some studies have highlighted a correlation between dysbiosis and the degree of disease progression, pocket depth<sup>7</sup>, and mucosal bleeding<sup>8</sup>. These findings raise the chicken and egg question: do immunological changes drive dysbiosis or does dysbiosis dictate the immunological changes?

A recent systematic review of patients with and without a supportive therapy programme showed that participation in the programme did not prevent mucositis, but did prevent peri-implantitis<sup>9</sup>. Because the oral biofilm triggers an increased inflammatory tissue response, controlling it reduces the progression of oral lesions with immunological pathogenesises, such as lichen. The same thing may apply to peri-implantitis, where the presence of plaque is like adding gasoline to a fire.

A systematic review found no changes in oral implant microflora after patients took probiotics, and no effect when probiotics were included in the non-surgical treatment of peri-implant mucositis and peri-implantitis<sup>10</sup>. However, using different species of bacteria may be more successful, and some recent data suggests *S. dentisani* is a better option than *L. reuteri*. There is also the question of the mode of administration. For instance, a bioactive healing abutment featuring a chamber containing clindamycin combined with a collagen carrier may improve mucositis by allowing the drug to be released gradually, with the potential to refill the abutment chamber<sup>11</sup>.

- 1 Carcuac O, Derks J, Abrahamsson I, Wennström JL, Berglundh T. *Risk for recurrence of disease following surgical therapy of peri-implantitis-A prospective longitudinal study.* Clin Oral Implants Res. 2020;31(11):1072-7. DOI:10.1111/clr.13653
- 2 Heitz-Mayfield LJA, Salvi GE, Mombelli A, Loup PJ, Heitz F, Kruger E, Lang NP. *Supportive peri-implant therapy following anti-infective surgical peri-implantitis treatment: 5-year survival and success.* Clin Oral Implants Res. 2018;29(1):1-6. DOI:10.1111/clr.12910
- 3 Rothschild D, Leviatan S, Hanemann A, Cohen Y, Weissbrod O, Segal E. *An atlas of robust microbiome associations with phenotypic traits based on large-scale cohorts from two continents.* PLoS One. 2022;17(3):e0265756. DOI:10.1371/journal.pone.0265756
- 4 Ghensi P, Manghi P, Zolfo M, et al. *Strong oral plaque microbiome signatures for dental implant diseases identified by strain-resolution metagenomics.* npj Biofilms Microbiomes 2020;6:47. DOI:10.1038/s41522-020-00155-7
- 5 Carvalho ÉBS, Romandini M, Sadilina S, Sant'Ana ACP, Sanz M. *Microbiota associated with peri-implantitis-A systematic review with meta-analyses.* Clin Oral Implants Res. 2023 Jul 31. DOI:10.1111/clr.14153
- 6 Sinjab K, Sawant S, Ou A, Fenno JC, Wang HL, Kumar P. *Impact of surface characteristics on the peri-implant microbiome in health and disease.* J Periodontol. 2023 Sep 4. DOI:10.1002/JPER.23-0205
- 7 Kröger A, Hülsmann C, Fickl S, et al. *The severity of human peri-implantitis lesions correlates with the level of submucosal microbial dysbiosis.* J Clin Periodontol. 2018;45(12):1498-509. DOI:10.1111/jcpe.13023
- 8 Li S, Sun F, Wei Y, Nie Y, Wu X, Hu W. *Mucosal bleeding correlates with submucosal microbial dysbiosis in peri-implant mucositis of patients with periodontitis.* Clin Oral Implants Res. 2023;34(9):947-57. DOI 10.1111/clr.14120
- 9 Carra MC, Blanc-Sylvestre N, Courtet A, Bouchard P. *Primordial and primary prevention of peri-implant diseases: A systematic review and meta-analysis.* J Clin Periodontol. 2023;50 Suppl 26:77-112. DOI:10.1111/jcpe.13790
- 10 Sayardoust S, Johansson A, Jönsson D. *Do Probiotics Cause a Shift in the Microbiota of Dental Implants-A Systematic Review and Meta-Analysis.* Front Cell Infect Microbiol. 2022;12:823985. DOI:10.3389/fcimb.2022.823985
- 11 Wychowanski P, Nowak M, Miskiewicz A, et al. *The Effectiveness of a Bioactive Healing Abutment as a Local Drug Delivery System to Impact Peri-Implant Mucositis: A Prospective Case Series Study.* Pharmaceuticals. 2022;15(1):138. DOI:10.3390/pharmaceutics15010138

ARTICLE OPEN

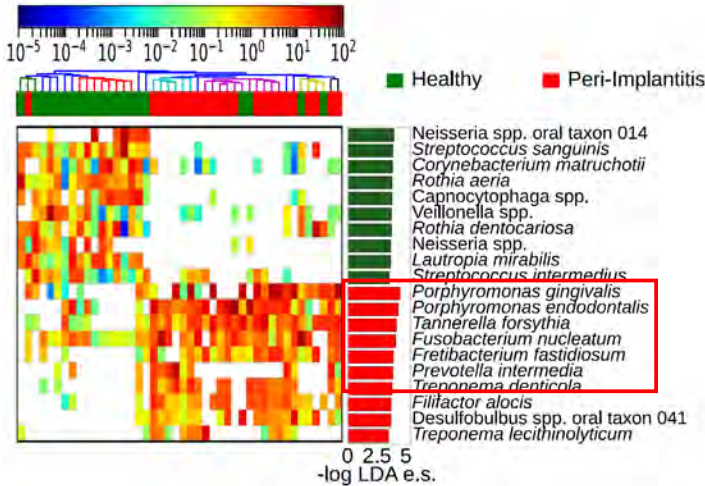


# Strong oral plaque microbiome signatures for dental implant diseases identified by strain-resolution metagenomics

Paolo Ghensi<sup>1,7</sup>, Paolo Manghi<sup>1,7</sup>, Moreno Zolfo<sup>1</sup>, Federica Armanini<sup>1</sup>, Edoardo Pasolli<sup>1</sup>, Mattia Bolzan<sup>1,6</sup>, Alberto Bertelle<sup>2</sup>, Federico Dell’Acqua<sup>2</sup>, Ester Dellasega<sup>2</sup>, Romina Waldner<sup>2</sup>, Francesco Tessarolo<sup>3,4</sup>, Cristiano Tomasi<sup>5</sup> and Nicola Segata<sup>1,8</sup>

**Table 1.** Demographic, anamnestic, and clinical characteristics of the sampled population.

	Healthy	Mucositis	Peri-implantitis	p value
No. of subjects	24	24	24	—
Age (mean (range))	62 (45–77)	63 (43–86)	62 (42–78)	0.83
Gender (M/F)	14/10	10/14	14/10	0.41
History of periodontitis (Y/N)	5/19	11/13	11/13	0.12
Smoking (Y/N)	2/22	7/17	7/17	0.13
Diabetes (n cases)	1	0	2	0.16
No. of implants (mean (SD))	3.6 (2.5)	3.8 (2.2)	4.1 (3.0)	0.82
No. of teeth (mean (SD))	20.1 (7.0)	17.8 (8.1)	18.4 (8.5)	0.20
Previous peri-implantitis (Y/N)	2/22	4/20	6/18	0.30
Frequency of home oral care (mean (SD))	2.1 (0.7)	2.3 (0.9)	2.0 (0.7)	0.33





# Asaf Wilensky

## Peri-implantitis: more than a bacterial infection

### Is the peri-implant immune response dysregulated in peri-implantitis?

A murine model developed by the speaker and his team has demonstrated that titanium implants impair the development of dendritic cells into Langerhans cells<sup>1</sup>. Previous studies have found that depletion of Langerhans cells around teeth leads to destructive immunity and severe bone loss<sup>2</sup>. Leukocytes have also been found to be more numerous around implants than in teeth, with the number of neutrophils six times higher<sup>3</sup>. The same pattern was observed for all lymphocyte subpopulations. Similarly, pro-inflammatory cytokines were all overexpressed in peri-implant tissue<sup>3</sup>. Taken together, these findings suggest a dysregulation of immune homeostasis. The RANKL/OPG ratio, considered a reliable indicator for bone loss, was also six times higher in implant sites than in tooth sites.

### Could dental implants affect remote sites?

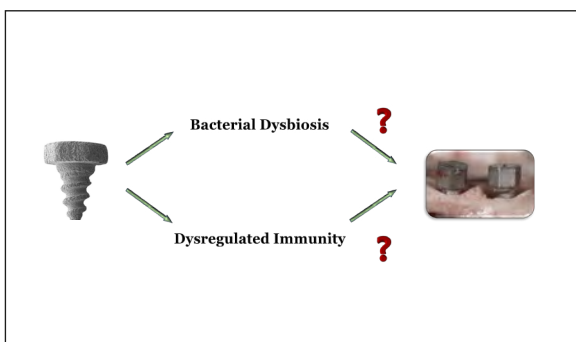
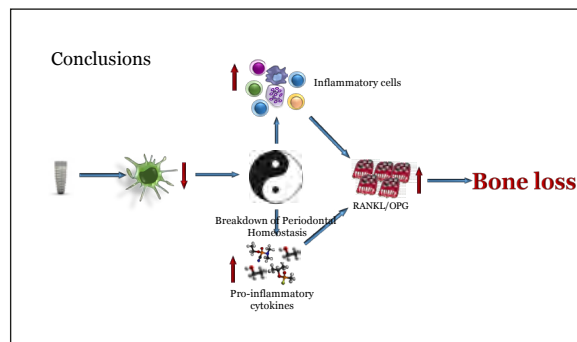
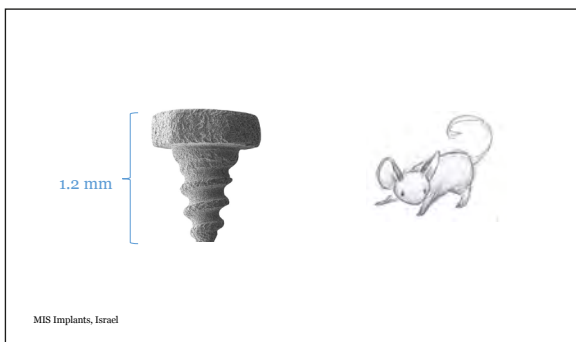
When the same authors harvested splenocytes from the mice that had received implants, they found these were significantly activated by peri-implant inflammation, compared with cells from the control group of mice<sup>18</sup>, suggesting a chronic remote activation mechanism.

In the mouse with implants, the contralateral periodontal tissues also showed elevated levels of all inflammatory markers and significantly more bone loss, indicating a reaction beyond the local response of the peri-implant inflammation.

### Could implant placement result in bacterial dysbiosis?

Dysregulation of the peri-implant immune response is associated with modifications to the microbiota. Bacterial loads are significantly higher and more diverse after implant placement<sup>3</sup>. There is also an increase in the proportion of periodontal pathogenic families and a decrease in the microflora associated with periodontal health<sup>3</sup>. It has been demonstrated that antibiotic treatment prevents bone loss around teeth, but fails to prevent the loss of implant-supporting bone, indicating that an additional mechanism besides bacterial dysbiosis is involved in peri-implantitis.

Another study showed a higher susceptibility of implants to pathogen-induced peri-implantitis. All immune cells and inflammatory biomarkers were significantly elevated compared to teeth. However, treatment with Resolvin D2 decreased infiltrated neutrophils and prevented bone loss<sup>4</sup>.



- Heyman O, Koren N, Mizraji G, et al. *Impaired Differentiation of Langerhans Cells in the Murine Oral Epithelium Adjacent to Titanium Dental Implants*. Front Immunol. 2018;9:1712. DOI:10.3389/fimmu.2018.01712
- Arizon M, Nudel I, Segev H, et al. *Langerhans cells down-regulate inflammation-driven alveolar bone loss*. Proc Natl Acad Sci U S A. 2012;109(18):7043-8. DOI:10.1073/pnas.1116770109
- Heyman O, Horev Y, Koren N, et al. *Niche Specific Microbiota-Dependent and Independent Bone Loss around Dental Implants and Teeth*. J Dent Res. 2020;99(9):1092-101. DOI:10.1177/0022034520920577
- Heyman O, Horev Y, Mizraji G, Haviv Y, Shapira L, Wilensky A. *Excessive inflammatory response to infection in experimental peri-implantitis: Resolution by Resolvin D2*. J Clin Periodontol. 2022;49(11):1217-28. DOI:10.1111/jcpe.13631

## Discussion

### Should implants be viewed like teeth or considered to be foreign bodies?

In the mouse model, homeostasis around implants was more vulnerable and susceptible to bacterial dysbiosis. Although the literature shows that the 'pocket microbiota' is very similar in periodontitis and peri-implantitis, the latter progresses clinically faster than the former and frequently with pus, indicating the presence of abundant neutrophils. It is unclear whether this response should be defined as a foreign body reaction, although it's evident that implants elicit a different immune response to teeth. Differences were also found between them at the protein level.

#### Can susceptibility be predicted in order to treat peri-implantitis?

The potential for biomarkers and genetics to predict the susceptibility of a patient to peri-implant diseases is real, but these tools are not ready for widespread clinical application. There is no immunological or proteomic analysis that will predict a patient's susceptibility to peri-implantitis. At the same time, the variability of the microbiome also prevents an accurate pre-diagnosis. Therefore, prevention remains the most effective strategy.

In terms of treatment, the future may lie more in immunomodulation than in antibiotics. It is well known that the biofilm rapidly re-established itself on implant surfaces, and antibiotics only delay the onset of disease, rather than eliminate it.

#### Differences between titanium and zirconia

No histological differences between titanium and zirconia can be observed in the late stages of peri-implantitis. However, ongoing studies have pointed to some material-dependent differences in the early stages of the disease.

Topography plays a role due to the impact it has on biofilm retention. As a result, implantoplasties can perform well clinically, even though particle dispersion may be a pathogenic factor. More evidence is needed on this point.

#### The future

Asaf Wilensky suggested that in the future regenerative dentistry, specifically the growth of new teeth, could overtake dental implants as the preferred option, although this is still in the early stages of research. Daniel Jönsson said that he hoped that in the not too distant future a new treatment for peri-implantitis based on the immunological response would become a reality. Tobias Fretwurst agreed, and said he anticipated that treatment in the future would also become more personalised.

# The frail patient: how to manage medical risk factors

This session provided a comprehensive overview of the therapeutic management of elderly and medically compromised patients, with a particular focus on the assessment of risk factors in patients with osteoporosis.

The speakers shared data relating to the inflammatory features of osteoporosis along with the risks associated with bisphosphonate therapy, its impact on alveolar bone and oral soft tissue and the consequences for dental implant therapy.

Bearing in mind that the average age of patients continues to increase, an awareness and understanding of the pathophysiology of age-related diseases and their influence on oral tissues is essential for dental surgeons. Such knowledge will help prevent complications and increase the likelihood of optimal long-term results in this significant group of patients with an important systemic disease.

## Elena Calciolari

### Chronic diseases immunocompromised patients – focus on osteoporosis

Chronic or non-communicable diseases are both multifactorial and highly prevalent. One in three adults suffers from multiple chronic conditions, and these are responsible for 74% of global deaths. As their prevalence increases with age, they are becoming an ever-more relevant factor in daily practice because of Europe's alarmingly fast ageing rate.

The interconnected role of a compromised immune system in elderly patients further contributes to the development of chronic inflammatory diseases. For example, the inflammatory response to periodontitis plays a role in triggering or exacerbating osteoporosis. Patients suffering from age-associated chronic diseases are characterised by non-resolving inflammation, a reduced ability to destroy bacteria and impaired healing. Osteoporosis, which is particularly prevalent in post-menopausal women, is mainly caused by oestrogen deficiency and results in an increased rate of bone remodelling accompanied by a permanent pro-inflammatory state. This perpetuates and increases bone loss<sup>1</sup>. The inflammatory osteolytic process, also called 'immunoporosis', is regulated by T cells which express pro-inflammatory mediators such as IL-6, IL-17 and RANKL. These also promote osteoclastogenesis and bone resorption.

Patients affected by osteoporosis present with reduced jaw bone mineral density increased risk of periodontitis and tooth loss<sup>2</sup>, delayed

or impaired bone regeneration<sup>3</sup> reduced implant osseointegration and increased marginal bone loss. Moreover, the combination of impaired angiogenesis and increased levels of pro-inflammatory mediators during osteoporosis further compromises bone healing, formation and maturation. Turning to implant placement, in pre-clinical models, osteoporosis is associated with reduced bone-to-implant contact area and impaired mechanical bone properties<sup>4</sup>.

Despite this, similar implant survival and success rates have been observed for implants placed in healthy and osteoporotic patients. On the other hand, a recent systematic review indicates that osteoporosis might be associated with a lower implant success rate and a greater risk of marginal bone loss where implants are placed in augmented bone<sup>5</sup>. As a result, they require special consideration during implant treatment planning, for instance allowing longer healing periods and favouring less invasive approaches.

The use of hydrophilic implants with a micro-rough surface is potentially beneficial in osteoporotic patients. This type of surface can downregulate the early pro-inflammatory response and promote osteogenesis and based on preliminary data from a case series it is associated with stable peri-implant bone levels after 12 months without the need for prolonged healing protocols prior to loading. As a result, hydrophilic implants can increase the likelihood of treatment

1 Shuler FD, Conjeski J, Kendall D, Salava J. *Understanding the burden of osteoporosis and use of the World Health Organization FRAX*. Orthopedics. 2012;35(9):798-805. DOI:10.3928/01477447-20120822-12.

2 Xu S, Zhang G, Guo JF, Tan YH. *Associations between osteoporosis and risk of periodontitis: A pooled analysis of observational studies*. Oral Dis. 2021;27(2):357-69. DOI:10.1111/odi.13531.

3 Tsukasaki M, Takayanagi H. *Osteoimmunology: evolving concepts in bone-immune interactions in health and disease*. Nat Rev Immunol. 2019;19(10):626-42. DOI:10.1038/s41577-019-0178-8.

4 Dereka X, Calciolari E, Donos N, Mardas N. *Osseointegration in osteoporotic-like condition: A systematic review of preclinical studies*. J Periodontal Res. 2018;53(6):933-940. doi: 10.1111/jre.12566.

5 Lemos CAA, de Oliveira AS, Faé DS, Oliveira HFFE, Del Rei Daltro Rosa CD, Bento VAA, Verri FR, Pellizzer EP. *Do dental implants placed in patients with osteoporosis have higher risks of failure and marginal bone loss compared to those in healthy patients? A systematic review with meta-analysis*. Clin Oral Investig. 2023;27(6):2483-93. DOI:10.1007/s00784-023-05005-2.

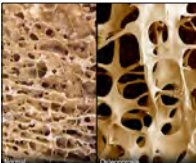
being successful and may be particularly recommended for complex procedures with simultaneous bone regeneration<sup>6</sup>.

Recognising the increasing number of older individuals with osteoporosis attending dental clinics, a focus on treatment that is personalised to the disease is particularly important. This should

take a number of factors into account, including individual risk profiles, systemic factors such as vitamin D deficiency, the role of anti-resorptive medications and the patient's low bone quality. From the physician's point of view, adopting minimally invasive procedures followed by a strict supportive care regimen will be necessary to maximise the long-term success of implant-supported therapy.

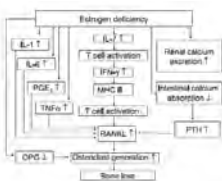
### OSTEOPOROSIS

"A systemic skeletal disease characterized by a decrease in bone mass and microarchitectural changes in bone which lead to an increased bone fragility and an increased risk of fractures"  
(Consensus development Conference 1993)




- ↓ BONE DENSITY
- ↑ BONE FRAGILITY
- ↑ FRACTURE RISK

### POST-MENOPAUSAL OSTEOPOROSIS




- ↑ bone resorption and bone remodeling
- ↑ remodeling rate (micro damage accumulation)
- ↑ inflammatory cytokines
- ↑ sensitivity to PTH (secondary hyperparathyroidism) and vit D deficiency

### OSTEOPOROSIS AND PERIODONTITIS



**OSTEOPOROTIC PATIENTS HAVE:**

- Increased **RISK OF PERIODONTITIS** (OR= 1.95)
- Increased % of sites with
  - CAL ≥4 mm**  
(3.04%, 95% CI 1.23, 4.85; p<0.001)
  - CAL ≥6 mm**  
(5.07%, 95% CI 2.74-7.42; p<0.001)
- Increased **TOOTH LOSS**  
-1.8 teeth after adjusting for smoking



1 2 3 4

### CLINICAL RECOMMENDATIONS

- RISK FACTORS DISEASES DRUGS**  
Control for **concomitant risk factors** that can affect bone metabolism and bone density (e.g. deficiencies of vitamin D and calcium, smoking, alcohol abuse) and **presence of systemic diseases** (e.g., diabetes mellitus) or **drug intake** (e.g., corticosteroids, SERMs, PPI) with a recognized impact on bone tissue
- BONE DENSITY**  
Consider **osteoporotic bone** as equivalent to **type IV** (Lekholm and Zarb classification), thus porous and on average of **poor quality**.
- IMPLANT OSTEOTOMY**  
When preparing the implant site, clinicians might consider **underpreparation** of the site and to allow for **longer healing periods** before sitting the prosthesis
- IMPLANT SURFACE**  
Take advantage of **implant surface** particularly in challenging conditions (? bone regenerative procedures)

### CLINICAL RECOMMENDATIONS

- SUPPORTIVE CARE**  
Establish strict **supportive care** programs as osteoporotic patients have increased risk of periodontitis (? peri-implantitis)
- MINIMAL INVASIVENESS**  
**Minimal invasiveness** (avoid second surgical site, no healing for secondary insertion to reduce risk of infections/MPRON, guided-surgery), use of biologics (?)
- CONSULTATION**  
**Consult** with the physician if needed

## PERSONALIZE YOUR TREATMENTS!

<sup>6</sup> Calciolari E, Hamlet S, Ivanovski S, Donos N. *Pro-osteogenic properties of hydrophilic and hydrophobic titanium surfaces: Crosstalk between signalling pathways in vivo models.* J Periodontal Res. 2018;53(4):598-609. DOI:10.1111/jre.12550.  
Mardas N, Schwarz F, Petrie A, Hakimi AR, Donos N. *The effect of SLActive surface in guided bone formation in osteoporotic-like conditions.* Clin Oral Implants Res. 2011;22(4):406-15. DOI:10.1111/j.1600-0501.2010.02094.x.



## Cecilia Larsson Wexell

### The frail patient and antiresorptive agents

Clinical frailty assessments of ageing patients take into account comorbidities, activities of daily living and cognition as a means of analysing the biological ageing of tissues. For instance, alveolar bone in the elderly patient is highly dense with a reduced number of blood vessels, which means that as osteoporosis develops, the incidence of fractures increases significantly<sup>1</sup>.

Anti-resorptive medications, such as bisphosphonates and denosumab, have traditionally been used both for the management of osteoporosis and osseous cancer, with denosumab, a monoclonal antibody treatment, introduced in 2011. Unfortunately, side-effects of this group of medications may induce medication-related osteonecrosis of the jaw (MRONJ), which is clinically challenging and impacts severely on the patient's quality of life<sup>2</sup>. As well as suppressing bone turnover, these drugs promote the adhesion of bacteria to bone, decrease angiogenesis, and lead to immune response dysfunction and soft tissue toxicity<sup>3</sup>. All this results in a marked increase in healing time following tooth extraction and an increased susceptibility of bone to infections<sup>4</sup>. It should also be noted that there are numerous non anti-resorptive

medications that have also been associated with an increased risk of developing osteonecrosis of the jaw.

Therefore, a comprehensive risk assessment needs to be carried out for each of these patients to include systemic and local factors such as age, comorbidities, and oral infections and hygiene. In particular, the patient's anti-resorptive treatment modality characteristics, such as type of agent, treatment duration, route of administration, and the role of other complementary therapies, requires special consideration. General dentists with less experience are often uncertain about the type of risk assessment that is required to perform surgical procedures in patients receiving anti-resorptive medication. Antibiotic treatment should also be considered carefully in such patients.

Finally, frail patients who are taking antiresorptive medication need to be highly motivated, and to comply with the clinician's treatment programme in order to increase the likelihood of successful long-term treatment outcomes.

## Risk assessment/evaluation/planning

### Treatment-related factors

Type of agent (potency)  
Combination of agents  
Duration of treatment  
Route of administration  
Other medication (chemotherapy, steroids, thalidomide, ATMPs)



<sup>1</sup> Boyde A, Kingsmill VJ. *Age changes in bone*. Gerodontology. 1998;15(1):25-34. DOI:10.1111/j.1741-2358.1998.00025.x.

<sup>2</sup> Elsayed R, El-Awady A, Cutler C, Kurago Z, Elashiry M, Sun C, Bloomquist R, Meghli MM, Elsalanty ME. *Matrix-Bound Zoledronate Enhances the Biofilm Colonization of Hydroxyapatite: Effects on Osteonecrosis*. Antibiotics (Basel). 2021;10(11):1380. DOI:10.3390/antibiotics10111380.

<sup>3</sup> Kos M, Junka A, Smutnicka D, Szymczyk P, Gluza K, Bartoszewicz M. *Bisphosphonates enhance bacterial adhesion and biofilm formation on bone hydroxyapatite*. J Craniomaxillofac Surg. 2015;43(6):863-9. DOI:10.1016/j.jcms.2015.04.018. Micheletti C, DiCecco LA, Larsson Wexell C, Binkley DM, Palmquist A, Grandfield K, Shah FA. *Multimodal and Multiscale Characterization of the Bone-Bacteria Interface in a Case of Medication-Related Osteonecrosis of the Jaw*. JBMR Plus. 2022;6(12):e10693. DOI:10.1002/jbm4.10693.

<sup>4</sup> Shudo A, Kishimoto H, Takaoka K, Noguchi K. *Long-term oral bisphosphonates delay healing after tooth extraction: a single institutional prospective study*. Osteoporos Int. 2018;29(10):2315-21. DOI:10.1007/s00198-018-4621-7.

## Risk assessment/evaluation/planning

### Patient-related factors

#### Systemic factors

Poor health  
Advanced age  
Chronic inflammatory disease  
Comorbidities  
Life style factors

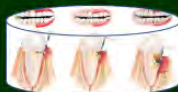

## Risk assessment/evaluation/planning

### Patient-related factors

#### Local factors

Odontogenic infections  
Dento-alveolar surgery  
Implant surgery  
Poor dental health status  
Ill-fitting dentures  
Exostosis  
Poor oral hygiene



## Discussion

### May different osteotomy methods, like underpreparation or osteodensification, lead to side effects in high risk patients?

So far there are no studies in the literature about this concern. In general, less invasive procedures and fewer interventions should be considered in high risk patients. For instance, sinus lifts should be avoided if possible.

### Does a drug holiday for patients being treated with denosumab have an influence on the fracture risk?

There is currently no evidence to show a reduction in fracture risk during a drug holiday from denosumab. However, when an extraction or implant placement is being planned, timing treatment to maximise the gap between doses of anti-resorptive drugs is optimal. Furthermore, prolonging the gap between the dental procedure and the time of taking the medication may be an option, as a planned delay in drug administration can favour socket and wound healing.

### Is there a recommended regime for systemic antibiotics for osteoporotic patients?

Practices differ from country to country. However, there is no evidence to clearly indicate a significantly decreased risk of infection

when administering antibiotics prior to simple extraction surgery. Therefore, the choice of whether to administer antibiotics to an osteoporotic patient should normally be based on the same criteria as patients without the condition. Antibiotics should, however be prescribed if there are signs of an infection. Another factor that should be considered is the capacity of the patient's tissue to heal after any intervention. Thus a combination of the patient's risk level and the diagnosis of the tooth to be extracted should be used to determine if they will benefit from the use of antibiotics.

### Can implants be placed in both low-risk and high-risk patients?

Implants can definitely be placed in low-risk patients (those taking lower doses of bisphosphonates for osteoporosis, compared with those taking higher doses for oncological reasons) providing a careful 'watchmaker' approach is taken, and as long as there are no other risk factors that need to be considered. By monitoring the healing capacity of the alveolar socket via X-ray, it is possible to predict whether osseointegration will be impaired in the case of posterior implant surgery. It is also advisable to opt for a late implant placement protocol rather than immediate placement – if possible – when considering patient risk.

# Peri-implant diseases reloaded: choice of material and shape

At the level of the abutment, some essential questions need to be asked. These include:

- Does the abutment material and surface influence the hard and soft tissue response?
- What is the potential impact of the abutment shape on the onset of peri-implantitis?

## Stefan Bienz

### The effect of abutment surface and abutment material on peri-implant health and diseases

Prevention of peri-implantitis must be prioritised since its treatment has limited success. The choice of abutment material and surface can be considered as a form of primordial prevention, with the aim of reducing risk factors for peri-implantitis <sup>1</sup>.

Taking a single aesthetic case as an example, the speaker illustrated six reconstruction choices:

- a) screw-retained porcelain fused to metal crown
- b) screw-retained zirconia crown cemented in the lab on a titanium base
- c) screw-retained zirconia crown cemented in the lab on a custom titanium abutment
- d) screw-retained one-piece zirconia crown
- e) zirconia crown cemented in the mouth
- f) porcelain fused to metal crown cemented in the mouth

The clinician should take three factors into account when considering which option to choose: aesthetics, function and biology. This presentation focused primarily on biological aspects.

Soft tissue repair and regeneration around a foreign body (in this case an implant or abutment) can proceed well both under tissue pressure, in the case of a second surgery for abutment connection, and when areas are left open for secondary healing, in the case of immediate implant placement and transmucosal healing.

The junctional epithelium is a specialised type of tissue with a high turnover of cells and weak surface attachment. It is well vascularised, allowing immunological cells to transit through it quickly to prevent bacteria from getting into the deeper part of the peri-implant sulcus.

Below the epithelium is the connective tissue, which is rich in densely packed collagen fibres which attempt to create a seal around the implant. On the other hand, there are few cells close to the surface of the implant and vascularisation is very poor.

Regarding the optimal abutment material for biocompatibility, experimental studies have shown that bone resorption and soft tissue recession is greater where gold and veneered gold abutments are used, compared with titanium, alumina or zirconia abutments<sup>2,3</sup>. PFM is thus not the ideal material. The deeper the emergence profile, the more critical material biocompatibility becomes, and the more important it is to avoid materials that can increase resorption or recession. Titanium and zirconia are thus the 'winners' of this first experiment.

Studies have compared titanium with zirconia in terms of bacterial growth, and greater biofilm accumulation has been observed on titanium discs<sup>4</sup>. Another RCT compared the clinical performance of the two materials by placing a titanium implant and a zirconia implant next to each other and concluded that the differences between them was very slight<sup>5</sup>. A recent systematic review comparing titanium and zirconia abutments observed similar bone level stability for both types of material, but a tendency towards greater plaque accumulation and more bleeding on probing in the titanium group, although this was non significant<sup>6</sup>. Based on this evidence, the speaker concluded that in the case of mucositis, zirconia may have a small advantage over titanium, particularly considering the desired (long) lifespan of restorations and the potential for mucositis to develop over time.

So, biologically speaking, the best solution is typically a one-piece zirconia crown. The abutment should not be veneered in the

1 Herrera D, et al. *Prevention and treatment of peri-implant diseases – The EFP S3 level clinical practice guideline*. J Clin Periodontol. 2023;50 Suppl 26:4-76. DOI: 10.1111/jcpe.13823

2 Abrahamsson I, Berglundh T, Glantz PO, Lindhe J. *The mucosal attachment at different abutments*. J Clin periodontol 1998;25(9):721-7. DOI:10.1111/j.1600-051x.1998.tb02513.x

3 Welander M, Abrahamsson I, Berglundh T. *The mucosal barrier at implant abutments of different materials*. Clin Oral Implants Res 2008;19(7):635-41 DOI: 10.1111/j.1600-0501.2008.01543.x

4 Scarano A, Piattelli M, Caputi S, Favero GA, Piattelli A. *Bacterial adhesion on commercially pure titanium and zirconium oxide disks: an in vivo human study*. J Periodontol. 2004;75(2):292-6. DOI:10.1902/jop.2004.75.2.292

5 Bienz SP, Hilbe M, Hüsler J, Thoma DS, Hämmerle CHF, Jung RE. *Clinical and histological comparison of the soft tissue morphology between zirconia and titanium dental implants under healthy and experimental mucositis conditions-A randomized controlled clinical trial*. J Clin Periodontol. 2021;48(5):721-33. DOI:10.1111/jcpe.13411

6 Sanz-Sánchez I, Sanz-Martin I, Carrillo de Albornoz A, Figuero E, Sanz M. *Biological effect of the abutment material on the stability of peri-implant marginal bone levels: A systematic review and meta-analysis*. Clin Oral Implants Res. 2018;29 Suppl 18:124-44. DOI:10.1111/clr.13293

deepest area since this can result in higher pocket depth values and more bleeding on probing at the five-year follow-up.<sup>7</sup>

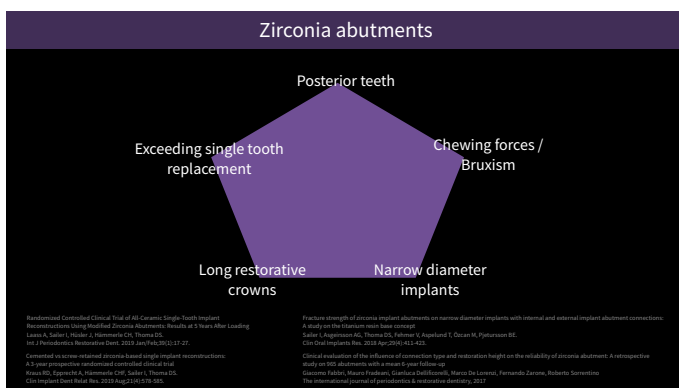
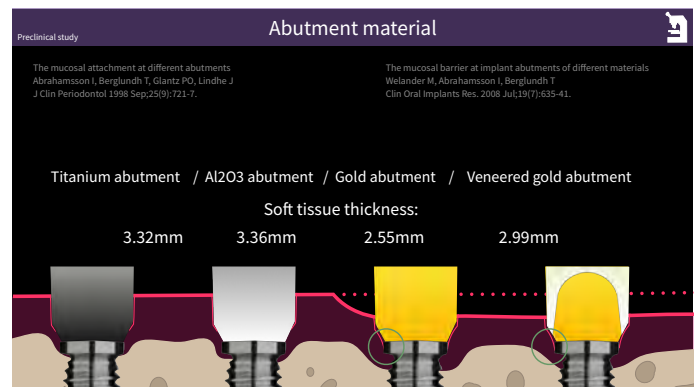
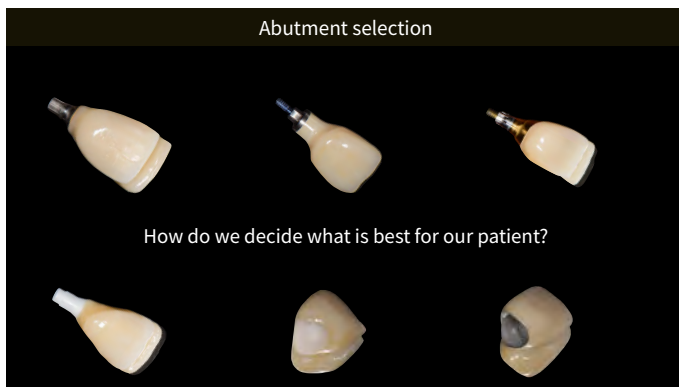
A clinical study on the performance of zirconia abutments with different connections showed a significantly lower survival rate for internal zirconia connections which also had a higher percentage of fractures. The authors also found that vertical reconstruction height was a risk factor height<sup>8</sup>. Technical limitations for this type of reconstruction are as follows:

- they should only be used for single-tooth replacements
- care should be taken when using them to replace posterior teeth
- chewing forces and bruxism should be taken into consideration
- the risks are higher with narrow-diameter implants
- risks are also higher for crowns with greater vertical height

Where there are technical risks, the speaker's preference was for a titanium custom abutment, which is more robust. This type of reconstruction has an extraorally cemented and polished interface.

These cementation interfaces demonstrated a high percentage of gaps before and after thermomechanical loading<sup>9</sup>. Although these cement margins are a biological issue, they can be placed coronally, away from the bone, to allow the supracrestal tissues to adapt correctly.

The proliferation and attachment of fibroblasts and epithelial cells to various surface topographies has been studied in vitro. Proliferation of fibroblasts is greater on zirconia than titanium. Rough surfaces favour fibroblast adhesion but not that of epithelial cells, while cell spreading is generally higher on polished and machined surfaces than on sandblasted surfaces<sup>10</sup>. The speaker concluded that the smoother, the better, adding that the millimetre closest to the implant platform could be slightly rough. By contrast, the rest of the abutment surface should be highly polished – even ultra-polished<sup>11</sup> – but no more than 0.2 Ra, a threshold value beyond which plaque accumulation no longer decreases.



7 Laass A, Sailer I, Hüsler J, Hämmerle CH, Thoma DS. *Randomized Controlled Clinical Trial of All-Ceramic Single-Tooth Implant Reconstructions Using Modified Zirconia Abutments: Results at 5 Years After Loading*. Int J Periodontics Restorative Dent. 2019;39(1):17-27. DOI:10.11607/prd.3792

8 Fabbri G, Fradeani M, Dellificorelli G, De Lorenzi M, Zarone F, Sorrentino R. *Clinical Evaluation of the Influence of Connection Type and Restoration Height on the Reliability of Zirconia Abutments: A Retrospective Study on 965 Abutments with a Mean 6-Year Follow-Up*. Int J Periodontics Restorative Dent. 2017;37(1):19-31. DOI:10.11607/prd.2974

9 Ioannidis A, Gil A, Hämmerle CH, Jung RE, Zinelis S, Eliades G. *Effect of Thermomechanical Loading on the Cementation Interface of Implant-Supported CAD/CAM Crowns Luted to Titanium Abutments*. Int J Prosthodont. 2020;33(6):656-62. DOI:10.11607/ijp.6709

10 Nothdurft FP, Fontana D, Ruppenthal S, May A, Aktas C, Mehraein Y, Lipp P, Kaestner L. *Differential Behavior of Fibroblasts and Epithelial Cells on Structured Implant Abutment Materials: A Comparison of Materials and Surface Topographies*. Clin Implant Dent Relat Res. 2015;17(6):1237-49. DOI:10.1111/cid.12253

11 Valantijene V, Mazeikiene A, Alkimavicius J, Linkeviciene L, Alkimaviciene E, Linkevicius T. *Clinical and immunological evaluation of peri-implant tissues around ultra-polished and conventionally-polished zirconia abutments. A 1-year follow-up randomized clinical trial*. J Prosthodont. 2023;32(5):392-400. DOI:10.1111/jopr.13670

## Oscar González Martín

### The effect of the emergence profile on peri-implant health and diseases

This presentation focused on the impact of the transmucosal component on the supracrestal tissues, especially the macroscopic design of the abutment. It discussed techniques for achieving a good biological seal and an optimal aesthetic outcome.

The intimate relationship between the abutment and the peri-implant mucosa is based on the weak adherence of the junctional epithelium and a sealing embrasure of collagen fibres in the connective tissue. A recent systematic review concluded that abutment characteristics did not significantly influence bone levels and peri-implant inflammation<sup>1</sup>. However, this is linked to an absence of evidence, rather than an absence of impact. Furthermore the unique characteristics and role of the provisional make it critical to the success of the final implant.

The author then talked further about the provisional, turning to the history of the emergence profile concept, which involves three main steps:

- In 1994, Nitzan Bichacho<sup>2</sup> set out the cervical contouring concept, establishing the necessity of a transitional submucosal implant-to-crown volume that follows the anatomical configuration of the natural tooth. However, sufficient soft tissue volume was needed to shape this, and mucosal margin apical migration could occur.
- In 2007, Eric Rompen<sup>3</sup> described the new concept of the concave transmucosal abutment as a means of reducing pressure and gaining stability, and as recently as 2022, an RCT demonstrated that a convex profile was associated with marginal recession<sup>4</sup>.
- The critical and subcritical contours were first defined in 2010<sup>5</sup>, and their importance was subsequently described in 2020<sup>6</sup>. According to the concept that was developed, there are two different areas of influence:
  - » The critical contour is the more superficial and is about 1 mm below the gingival margin. It determines the gingival margin: changing the former changes the latter.
  - » The subcritical contour is located more apically. Shaping this area changes tissue support, influencing tissue colour and the appearance of root convexity.

Two scenarios can be considered: immediate implant placement, or abutment placement in mature tissues. When placing an immediate transmucosal implant, the primary goal should be to support

the soft tissue in order to prevent margins from collapsing. As a result, customised healing abutments have aesthetic and biological advantages over standard ones<sup>7, 8</sup>. However, it is important to assess whether a favourable gingival margin is present and a supporting abutment is required, or whether volume is lacking and more open space should be left. Compression and convex contours must always be avoided. The subcritical contour should be as concave as possible, leaving space for the coagulum to form, followed by subsequent tissue differentiation.

However, the situation is different in delayed restoration following tissue maturation. In cases when healing has been ideal and tissue volume is sufficient, the definitive restoration should mirror the profile. The challenge is how to use the restoration to improve the situation in cases of non-ideal healing. As well as soft tissue augmentation, there is the option of sculpting the tissues. Once the critical contour is correct, reducing or increasing the subcritical contour can modify the appearance of the soft tissue, provided that there is enough height and volume of tissue (which requires deep implant placement).

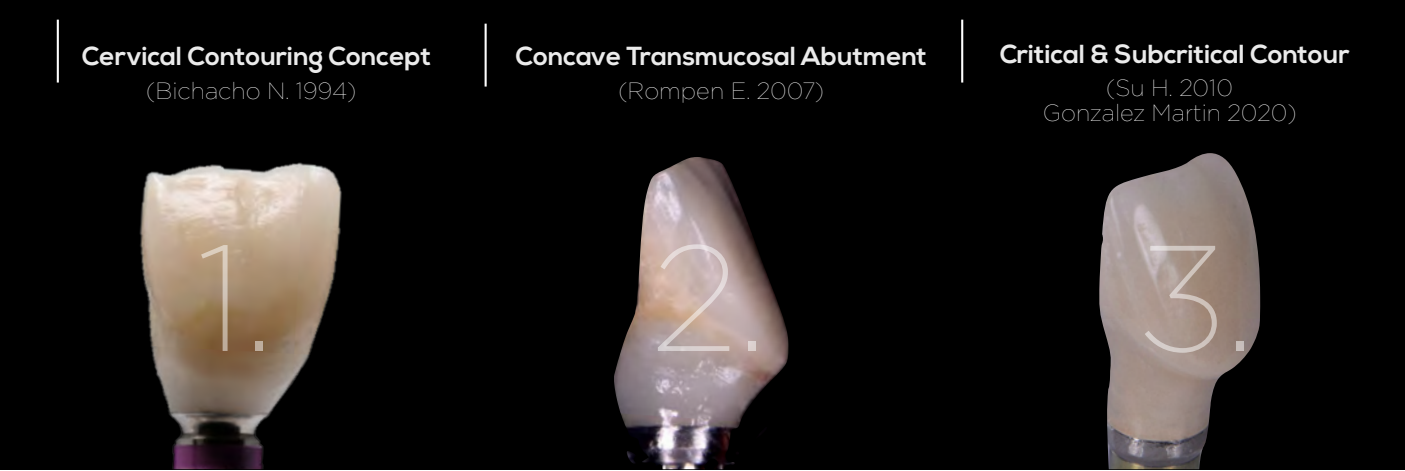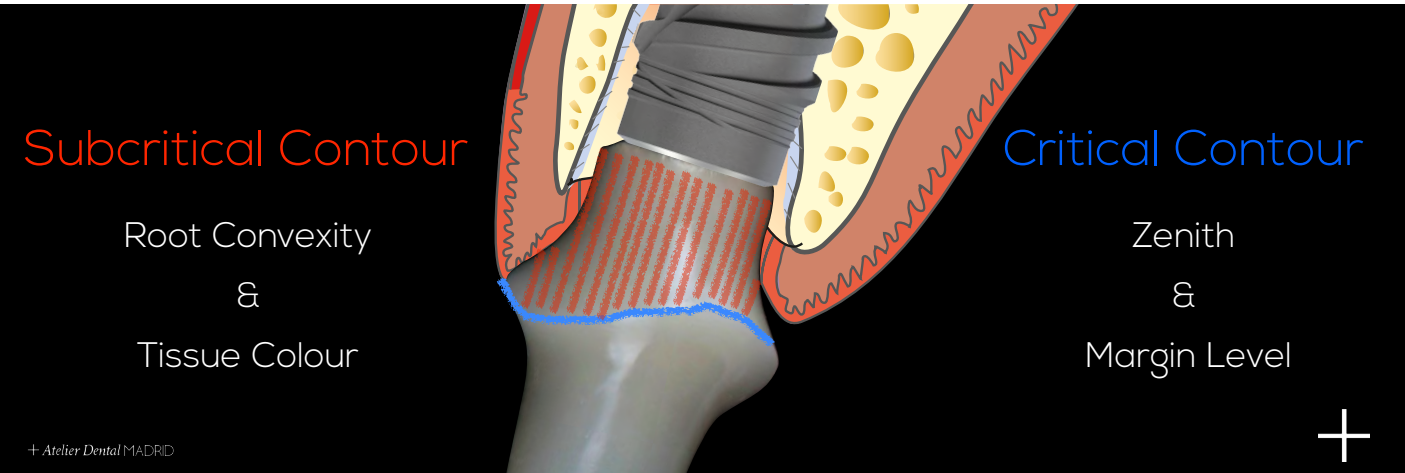
Evidence on the biological impact of the multiple abutment disconnections that are required to sculpt the peri-implant mucosa is controversial. Other factors have been demonstrated to trigger peri-implant inflammation, such as those related to abutment configuration<sup>9</sup>, which influence the ability to keep it clean. At the same time, more information is needed on the role of over-contoured restorations on the onset of peri-implantitis.

A stock abutment can be biologically safe, but the profile is not individualised, which will have a negative impact on soft tissue contour. Use of this type of abutment has significant limitations:

- Contour management should be adapted to the 3D position of the implant, and some malpositions, like a shallow implant position, cannot be fixed.
- The height of the abutment platform should be related to implant depth, leaving sufficient room for tissue management.
- The peri-implant phenotype needs to be taken into account<sup>10</sup>: a soft tissue graft is often needed in thin phenotype cases (defined as keratinised mucosa width and thickness < 2mm; supracrestal tissue height < 3mm; marginal bone thickness < 2mm).

- 1 Sanz-Martín I, Sanz-Sánchez I, Carrillo de Albornoz A, Figuero E, Sanz M. *Effects of modified abutment characteristics on peri-implant soft tissue health: A systematic review and meta-analysis*. Clin Oral Implants Res. 2018;29(1):118-29. DOI:10.1111/clr.13097
- 2 Bichacho N, Landsberg CJ. *A modified surgical/prosthetic approach for an optimal single implant-supported crown. Part II. The cervical contouring concept*. Pract Periodontics Aesthet Dent. 1994;6(4):35-41; quiz 41. PMID: 8054640.
- 3 Rompen E, Raepsaet N, Domken O, Touati B, Van Dooren E. *Soft tissue stability at the facial aspect of gingivally converging abutments in the esthetic zone: a pilot clinical study*. J Prosthet Dent. 2007;97(6 Suppl):S119-25. DOI:10.1016/S0022-3913(07)60015-8
- 4 Siegenthaler M, Strauss FJ, Gamper F, Hämmerle CHF, Jung RE, Thoma DS. *Anterior implant restorations with a convex emergence profile increase the frequency of recession: 12-month results of a randomized controlled clinical trial*. J Clin Periodontol. 2022;49(11):1145-57. DOI:10.1111/jcpe.13696
- 5 Su H, Gonzalez-Martin O, Weisgold A, Lee E. *Considerations of implant abutment and crown contour: critical contour and subcritical contour*. Int J Periodontics Restorative Dent. 2010;30(4):335-43. PMID: 20664835.
- 6 González-Martín O, Lee E, Weisgold A, Veltri M, Su H. *Contour Management of Implant Restorations for Optimal Emergence Profiles: Guidelines for Immediate and Delayed Provisional Restorations*. Int J Periodontics Restorative Dent. 2020;40(1):61-70. DOI:10.11607/prd.4422
- 7 Ruales-Carrera E, Pualetto P, Apaza-Bedoya K, Volpato CAM, Özcan M, Benfatti CAM. *Peri-implant tissue management after immediate implant placement using a customized healing abutment*. J Esthet Restor Dent. 2019;31(6):533-41. DOI:10.1111/jerd.12512
- 8 Perez A, Caiazzo A, Valente NA, Toti P, Alfonsi F, Barone A. *Standard vs customized healing abutments with simultaneous bone grafting for tissue changes around immediate implants. 1-year outcomes from a randomized controlled clinical trial*. Clin Implant Dent Relat Res. 2020;22(1):42-53. DOI: 0.1111/cid.12871
- 9 Souza AB, Alshihri A, Kämmerer PW, Araújo MG, Gallucci GO. *Histological and micro-CT analysis of peri-implant soft and hard tissue healing on implants with different healing abutments configurations*. Clin Oral Implants Res. 2018;29(10):1007-15. DOI:10.1111/clr.13367
- 10 Avila-Ortiz G, Gonzalez-Martin O, Couso-Queiruga E, Wang HL. *The peri-implant phenotype*. J Periodontol. 2020;91(3):283-8. DOI:10.1002/JPER.19-0566





DELAYED IMPLANTS						
	Facial soft tissue margin coronal to ideal level	Facial soft tissue margin at ideal level	Facial soft tissue margin slightly apical to ideal level	Interproximal tissue preserved	Interproximal tissue slightly deficient	Palatal
CRITICAL CONTOUR	Overdimension in facial/apical direction	Equal to the natural tooth	Underdimension in a facial direction	Equal to the natural tooth	Equal to the natural tooth	Equal to the natural tooth
SUBCRITICAL CONTOUR	Flat or slightly concave	Flat or slightly concave	Increase convexity	Equal to the natural tooth	Increase convexity	Equal to the natural tooth

Gonzalez-Martin O, et al. Contour Management of Implant Restorations for Optimal Emergence Profiles: Guidelines for Immediate and Delayed Provisional Restorations  
Int J Periodontics Restorative Dent 2020;40:61–70

+ Atelier Dental MADRID

+

## Discussion

### One abutment on time

A Kotouzis et al. meta-analysis<sup>1</sup> concluded that additional abutment disconnection and reconnection significantly affected peri-implant marginal bone levels. The bone loss for bone-level implants might be estimated at 0.2mm. As it is a multifactorial process, there is a lack of precise information, and it would be helpful to have an expert consensus on this issue.

### Depth of implant

Many clinicians consider deeper or slightly palatal implant placement to be a prudent choice, particularly in the aesthetic zone. However, changing the optimal position of the implant leads to variations in the emergence profile, which is biologically compromised by the implant position. The appropriate implant depth cannot be generalised. It must be based on factors including the individual situation, type of implant, connection, implant diameter, placement protocol, and whether augmentation is required or not. A cocktail of elements needs to be balanced before a decision is made.

### Timing of tissue response

From provisional to definitive, what is lost does not come back. During the provisional phase, the tissue becomes structured in front of composite, which is biologically a non-ideal material. Therefore, the preferred option is to go for a definitive abutment from the outset when this is possible. On the other hand, there is evidence that the junctional epithelium tolerates subgingival composites. Four weeks is usually enough time to shape the emergence profile, but the timing depends on the clinician's working style.

### Cleanliness

Clinicians work with abutment surfaces as received from the lab, without any controls. The chairside approach is never free from contamination, and some degree of inflammation should be expected in the provisional phase, although severe consequences are not generally seen.

### Abutment height

Although there is still no clinical evidence, cemented interfaces should not be close to the implant platform, nor should veneering material be submucosal.

<sup>1</sup> Kotouzis T, Gholami F, Reynolds J, Lundgren T, Kotsakis GA. *Abutment Disconnection/Reconnection Affects Peri-implant Marginal Bone Levels: A Meta-Analysis*. Int J Oral Maxillofac Implants. 2017;32(3):575–81. DOI:10.11607/jomi.5367

# The frail patient: how to manage physical and mental deterioration

- The demand for dental care in the elderly is increasing, but how exactly should it be provided?
- How can we assess the vulnerable patient?
- What are the particular issues associated with dental implants in older individuals?

This session highlighted the importance of a comprehensive and personalised approach.

## Martin Schimmel

### The frail patient: biological and functional decline

As people age, they often experience tooth loss due to tooth decay or periodontal disease. Loss of teeth can make it difficult to chew food, can affect speech, and can alter facial aesthetics, all of which can have a significant impact on the quality of life of older people<sup>1</sup>. Dental implants have become an effective approach for restoring oral function and aesthetics in the elderly.

#### Frailty

*Frailty* is a geriatric syndrome characterised by decreased physical endurance and a reduced ability to perform daily activities without assistance. As people age, they may become more susceptible to frailty due to a number of factors, including loss of muscle mass, reduced bone density and a decrease in strength. Frailty can have a significant impact on the independence and quality of life of older people, and good dental care is an important aspect in helping to prevent it.

The relationship between frailty and oral health is bidirectional. On the one hand, older people often experience declining oral health, such as tooth loss, dry mouth and chewing difficulties. These problems contribute to frailty by limiting oral function and making it harder to maintain an adequate diet, leading to a reduced quality of life. On the other hand, frailty and weakness make it difficult for elderly subjects to maintain oral hygiene measures, or handle dental prostheses adequately.

#### Oral frailty assessment

*Oral frailty* is a concept that has been developed to better understand the relationship between oral health and frailty in older people. Assessing oral frailty involves measuring several factors, including chewing function, tongue pressure, swallowing ability and mouth

dryness<sup>2</sup>. These indicators help dental health professionals identify older people at risk of frailty and develop personalised care strategies.

#### Dental implants in older people

Dental implants are an effective option for improving oral stability and function in older people. Implants can provide a long-lasting solution to replacing missing teeth<sup>3</sup>. However, it is essential to consider the challenges related to oral hygiene in older people, as they find it difficult to maintain adequate cleanliness around implants.

#### Functional assessments and quality of life assessments

In addition to measuring physical aspects such as tongue pressure and chewing ability, it is important to assess quality of life and perceived oral function in older people. In addition to functional tests, questionnaires can provide a more complete understanding of the patient's needs. Asking patients about weight loss and eating-related quality of life can help identify underlying problems and improve care.

#### Challenges in dental care for the old and very old

Dental professionals need to tailor treatments to the specific abilities and needs of older patients. This may include preserving natural teeth wherever possible, avoiding removable dentures, and providing personalised treatments. Prevention and proper care are essential to maintaining oral health in old age.

The demand for dental services for older patients is increasing as the population ages and life expectancy increases.

1 Schimmel M, Aarab G, Baad-Hansen L, Lobbezoo F, Svensson P. *A conceptual model of oro-facial health with an emphasis on function*. J Oral Rehabil. 2021;48(11):1283-94. DOI:10.1111/joor.13250

2 Arakawa I, Igarashi K, Imamura Y, Muller F, Abou-Ayash S, Schimmel M. *Variability in tongue pressure among elderly and young healthy cohorts: A systematic review and meta-analysis*. J Oral Rehabil. 2021;48(4):430-48. DOI:10.1111/joor.13076  
Schimmel M, Rachais E, Al-Haj Husain N, Müller F, Srinivasan M, Abou-Ayash S. *Assessing masticatory performance with a colour-mixing ability test using smartphone camera images*. J Oral Rehabil. 2022;49(10):961-9. DOI:10.1111/joor.13352

3 Enking N, Raueter M, Worn A, Muller F, Leles CR, Schimmel M. *A prospective cohort study on survival and success of one-piece mini-implants with associated changes in oral function: Five-year outcomes*. Clin Oral Implants Res. 2019;30(6):570-7. DOI:10.1111/cir.13444.

## Frail older adults

*u<sup>b</sup>*

UNIVERSITÄT  
DUISBURG  
ESSEN

- > Frail older adults more likely to show poor oral health, poor oral function and vice versa
- > Poor oral health: impact on overall health and well-being



www.eaothefirst.it/online/eaomuniversity.com/eaom-university

10


## Implant survival 1- and 5-year, Post-Loading

*u<sup>b</sup>*

ITI

UNIVERSITÄT  
DUISBURG  
ESSEN

- > Advanced age alone (>75 years) is not a contraindication for implant therapy.
- > In geriatric patients, implant therapy may be considered irrespective of age.
- > Implant and denture maintenance must be assured by the patient and/or care provider.



Schimmel, M., Shrivastava, M., McKenna, G., & Müller, F. (2018). Effect of advanced age and/or systemic medical conditions on dental implant survival: A systematic review and meta-analysis. Clin Oral Implants Res. 29(Suppl. 16), 311-330.

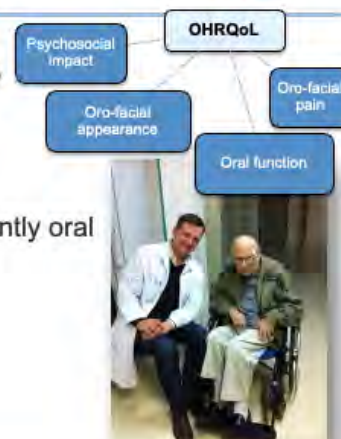48

## Conclusions

*u<sup>b</sup>*

UNIVERSITÄT  
DUISBURG  
ESSEN

- > Preserve teeth! Avoid dentures if possible!
- > Evaluate function (e.g. chewing gum, carrot, PaTaKa)
- > Evaluate OHRQoL (OHIP-14, GOHAI)
- > Inquire about dietary changes, weight loss
- > Implants may improve denture stability and consequently oral function, even in the care-dependent
- > Involve the family and care-takers
  - treatment decisions
  - oral hygiene measure
  - choice of food consistency



55

## Joke Duyk

### Mental deterioration: prosthodontic concepts

Prosthodontics in patients with cognitive impairment is an area that requires a deep understanding and a meticulous approach due to the unique nature of the intersection between cognitive and oral health.

Dementia significantly impacts the ability of individuals to engage in preventive care and oral hygiene practices. Resulting poor oral health directly affects the patient's quality of life and overall health, indicating a need for proactive and adaptive interventions by dental professionals<sup>1</sup>.

#### Patient assessment and treatment adaptation

Due to the fluctuating nature of cognitive impairment, each patient presents a unique set of challenges and needs. A lack of robust evidence to guide clinical decision-making further complicates this process. Therefore, a detailed assessment that takes into account modifying and influencing factors such as the patient's general health, medications, behaviour and social environment is advocated in order to formulate a workable and personalised treatment plan.

Dental interventions must take into account the difficulties that patients with cognitive impairment may have in tolerating standard procedures. This may include using techniques that minimise stress and discomfort, opting for less invasive procedures where possible, and considering sedation and other aids to facilitate treatment.

#### Effective communication and the role of caregivers

The importance of clear and compassionate communication with patients and, crucially, their carers was emphasised. Since caregivers play an integral role in implementing post-treatment care and daily oral hygiene, their understanding of instructions and ability to communicate problems or changes is critical<sup>2</sup>.

#### Modifying factors

In the context of prosthodontics and cognitive impairment, modifying factors are variables that can alter treatment outcomes<sup>3</sup>. These include lifestyle habits (such as diet and smoking), the presence of other medical conditions, and the ability of the patient and their support network to maintain consistent oral hygiene practices. Identification and proper management of these factors is essential to improving treatment outcomes.

In summary, this presentation provided a comprehensive view of prosthodontic care for patients with cognitive impairment, underscoring the need for an empathetic and adaptive approach. The presentation illustrated the importance of going beyond standard dental treatment protocols and advocating for a practice that recognises the dignity, limitations, and unique needs of this vulnerable population.

### Planning for a shortened dental arch restoring towards SDA

- Consider the condition of all remaining teeth

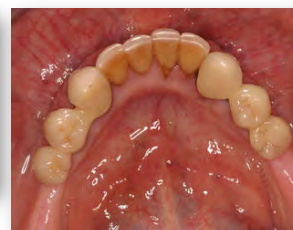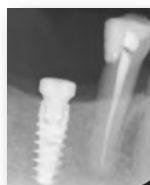*load-bearing capacity, restorative status, wear, durability, etc.*

- Consider tooth migration

- Horizontal and rotational migration
- Distal migration of premolars in SDA
- Missing antagonistic teeth
  - Over eruption in 83.9% (Kliaridis et al. 2000)
  - Majority of over eruption in first 12 months
  - In case of over eruption: 24% move over 2mm (Craddock & Youngson 2004)

- Consider patient's (para)function

- Consider patient's wishes, expectations



McKenna G, Jawad S, Darcey J. Functionally orientated tooth replacement for older patients. *Prim Dent J* 2020  
Kliaridis et al. Vertical position, rotation, and tipping of molars without antagonists. *Int J Prosthodont* 2000  
Craddock & Youngson. Eruptive tooth movement – the current state of knowledge. *Br Dent J* 2004

1 Müller F. *Interventions for edentate elders-what is the evidence?* Gerodontology. 2014;31 Suppl 1:44-51. DOI:10.1111/ger.12083

2 Geddis-Regan A, Errington L, Abley C, Wassall R, Exley C, Thomson R. *Enhancing shared and surrogate decision making for people living with dementia: A systematic review of the effectiveness of interventions.* Health Expect. 2021;24(1):19-32. DOI:10.1111/hex.13167

3 Ettinger R, Marchini L, Hartshorn J. *Consideration in planning dental treatment of older adults.* Clin Geriatric Med 2023;39(2):311-26. DOI:https://doi.org/10.1016/j.cger.2023.01.002.



## SHARED DECISION MAKING AID

**Let your dentist know about your dental care preferences**

Before your dental visit it can be useful to think about what matters to you with your dental care. This form helps you to think about your preferences and expectations. You can discuss your answers with your dentist at your appointment.

You can fill this out on your own, with a friend, family member, carer or with your dentist

Your full name: \_\_\_\_\_  
 Your preferred name: \_\_\_\_\_  
 Date of birth: \_\_\_\_\_  
 Your dental practice or service: \_\_\_\_\_  
 Who supports you with decision making: \_\_\_\_\_  
 Do you have a Lasting Power of Attorney for health? \_\_\_\_\_  
 Please tell us about any problems you have with your teeth or mouth: \_\_\_\_\_

**Please tick one box for each statement:**

	Disagree	Agree	Unsure	I'd like to discuss with my dentist
It's important to me that my teeth look good	<input type="checkbox"/>	<input type="checkbox"/>	<input type="checkbox"/>	<input type="checkbox"/>
I want my teeth to be left alone if they are not causing me pain	<input type="checkbox"/>	<input type="checkbox"/>	<input type="checkbox"/>	<input type="checkbox"/>
I am happy to sit in the dental chair for as long as it takes to fix a broken tooth	<input type="checkbox"/>	<input type="checkbox"/>	<input type="checkbox"/>	<input type="checkbox"/>
Visiting the dentist makes me scared or anxious	<input type="checkbox"/>	<input type="checkbox"/>	<input type="checkbox"/>	<input type="checkbox"/>
I don't mind having teeth removed if it means I have less pain	<input type="checkbox"/>	<input type="checkbox"/>	<input type="checkbox"/>	<input type="checkbox"/>
I would want dentures to replace missing teeth if possible	<input type="checkbox"/>	<input type="checkbox"/>	<input type="checkbox"/>	<input type="checkbox"/>
Being able to eat whatever I want is important to me	<input type="checkbox"/>	<input type="checkbox"/>	<input type="checkbox"/>	<input type="checkbox"/>

Please use the space below to tell us more about your answers above or write any questions you have for the dentist.

Please return this form to your dentist or bring it to your next visit. You can talk to the dentist about these answers and anything else concerning your treatment during your next visit.

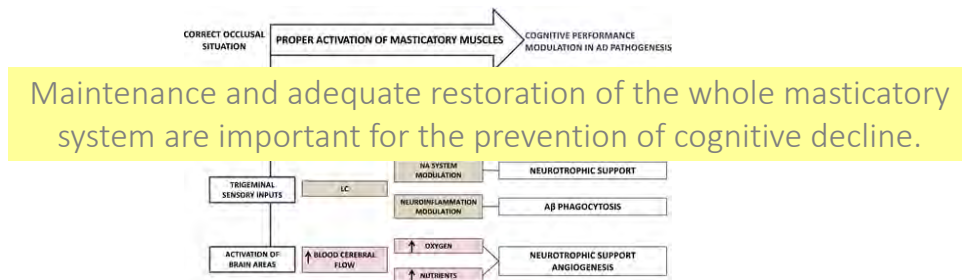
Newcastle University | Lab 4 Living

Geddis-Regan A., Exley C., Abley C., Durham J., Wassall R. Newcastle University

## MASTICATION - COGNITION

Many studies (animal/human) indicate relation/interconnection

Limited evidence for causal link in human studies



Hedberg et al. White matter abnormalities mediate the association between masticatory dysfunction and cognition among older adults. *J Oral Rehab* 2023

Lahoud & King. Masticatory dysfunction in older adults: a scoping review. *J Oral Rehab* 2023

Yeung & Leung. Functional neuroplasticity of adults with partial or complete denture rehabilitation with or without implants. Evidence from fMRI studies. *Nutrients* 2023

Li et al. Tooth loss and the risk of cognitive decline and dementia: a meta-analysis of cohort studies. *Front Neurol* 2023

Wei et al. Association between adverse oral conditions and cognitive impairment: a literature review. *Front Public Health* 2023

Nakamura et al. Oral dysfunctions and cognitive impairment/dementia. *J Neurosci Res* 2023

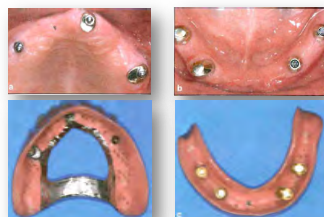Lopez-Chalchia et al. Oral health and healthy chewing for healthy cognitive ageing: a comprehensive narrative review. *Gerodontology* 2021

Daly et al. Evidence summary: the relationship between oral health and dementia. *Br Dent J* 2018

Tran, Krausch-Hofmann, Duyck, de Almeida Mello, De Lepeleire, Declercq, Declercq, Lesaffre. Associations oral & general health indicators in older adults. *Sci Rep* 2018

## Responding to a (f)ailing dentition

- Commit to tooth (root) retention
- Use (and combine) both teeth and implants to support a (existing) denture



Kaufmann et al. *Int J Prosthodont* 2009

Kaufmann et al. *Int J Prosthodont* 2009, Verma et al. *J Prosthet Dent* 2013, Frish et al. 2014, Rinke et al. *J Prosthodont* 2014, Rammelsberg et al. *Clin Oral Implants Res* 2014, Kapadia et al. *Dent Res J* 2022, Kuroshima et al. *J Prosthodont Res* 2023

## Discussion

### Patient communication

Effective communication with patients and their caregivers is vital, especially in situations where the patient may have difficulty expressing their preferences. To do this, it's necessary to pay attention to non-verbal responses and consider the opinions and observations of carers, who can offer valuable insights into what may be important to the patient, such as dental aesthetics, which may go unnoticed by the health professional.

### Delicate decisions

Decisions about dental treatment should not be made for the patient, but 'on behalf of' the patient. Consideration should be given to what the individual would have decided if he or she had the cognitive capacity to do so. This approach requires deep empathy and understanding, putting oneself in the patient's shoes to maintain their dignity and ensuring their personal preferences are at the centre of the decision-making process.

### Weight loss and nutrition

A crucial issue is the treatment of patients who have been referred because of weight loss, which is often perceived as a red flag for urgent dental intervention, such as the need for new dentures. However, it was argued that before proceeding with interventions

such as implants, the function of existing dentures should be assessed and other possible reasons for weight loss considered.

### Implants and nutritional advice

Although implants can improve chewing function, they do not necessarily lead to improved nutrition if the patient does not adjust their diet. Nutrition is a learned behaviour, and simply restoring the ability to chew does not mean that patients will choose more nutritious foods. Therefore, implant placement should be accompanied by nutritional advice to ensure that patients take full advantage of their new found functional improvement in order to adopt a healthier diet.

### Conclusion

Providing dental care to patients with special needs, particularly those with cognitive impairment, is complex and requires sensitivity. It is not just about restoring dental function, but requires an approach that also considers the patient's dignity, lifestyle preferences and overall well-being. Effective communication, empathy in decision-making and consideration of broader issues such as nutrition are essential. Good patient care will often involve combining medical interventions with counselling and education, as in the case of dental implants and nutritional advice, in order to achieve results that truly improve the patient's quality of life.

# How to handle patients with stage IV periodontitis

This session considered different treatment options for patients with stage IV periodontitis. It looked at options for patients with fixed versus removable prostheses, acknowledging that different treatment approaches can sometimes be complementary. The speakers described how to approach difficult cases focusing on the teeth that can still be maintained as the basis for the treatment.

## Alberto Fonzar

### How to handle patients with stage IV periodontitis: fixed restorations

This presentation focused on treating patients with stage IV periodontitis who have a fixed prosthesis. Patients in the stage IV category are defined as having at least 5mm of bone loss in five or more teeth, extending to the middle or apical third of the root. They often require complex rehabilitation due to masticatory dysfunction, secondary occlusal trauma and bite collapse.

According to the European Federation of Periodontology guidelines<sup>1</sup>, treatment of patients with stage IV periodontitis can be divided into four groups:

- Type 1: presenting with hyper-mobility and secondary occlusal trauma
- Type 2: presenting with pathological tooth migration
- Type 3: presenting with partial edentulism that is restorable without full-arch rehabilitation
- Type 4: presenting with the need for full-arch rehabilitation

The fixed rehabilitation approach is based on a combination of periodontal and prosthetic factors and includes three phases:

1. Eliminating tooth or site periodontal risk factors
2. Extracting teeth if the periodontal risk factors cannot be completely eliminated
3. Using the remaining teeth as abutments for a fixed rehabilitation known as a periodontal prosthesis (for this kind of treatment to be viable at least four remaining teeth are needed)<sup>2</sup>.

A comprehensive implant-based solution had previously been prescribed for patients with advanced periodontitis. However, the above protocol is currently recognised as the preferred option, because it has been accepted that implant-supported rehabilitations do not perform better than tooth-supported ones.

The speaker acknowledged that he has changed some aspects of his approach since he first presented it in the 2006 EAO Congress. The first factors to consider are the patient's wishes and their financial situation – namely whether or not they can afford the treatment. If so, the process begins by extracting the hopeless teeth, although tooth status can be only established following periodontal maintenance therapy<sup>3</sup>, and implant placement should be delayed for as long as possible until the disease is under control<sup>4</sup>. The speaker recommended waiting 1–2 months before re-evaluating the tooth after non-surgical therapy, as in some cases the desired periodontal goal takes longer to achieve than others. The speaker no longer recommended crowning or splinting teeth as the evidence suggests that this increases the risk of vertical fractures and tooth loss<sup>5</sup>.

Turning to the question of whether a prosthesis should be tooth- or implant-supported, the speaker referred to the biological cost/benefit of the two approaches. He explained that if the adjacent teeth are virgin, implants are his first choice as this avoids the need to prosthetically prepare the teeth. He again emphasised that there should always be a focus on saving teeth, noting that 'properly single rooted teeth can resist everything except dentists'. His final recommendation was to not only consider tooth- and site-related factors, but also patient-related risk factors, which can greatly influence the treatment outcome.

The conclusions of the presentation were as follows:

- tooth preparation to splint the abutments together and reduce secondary occlusal trauma might no longer be justifiable, and can be avoided by supporting occlusion using implant abutments
- tooth preparation is a risk factor per se, especially if the teeth have to be endodontically treated

<sup>1</sup> Herrera D, Sanz M, Kebschull M, Jepsen S, Sculean A, Berglundh T, Papapanou PN, Chapple I, Tonetti MS; EFP Workshop Participants and Methodological Consultant. *Treatment of stage IV periodontitis: The EFP S3 level clinical practice guideline*. J Clin Periodontol. 2022;49 Suppl 24:4-71. DOI:10.1111/jcpe.13639.

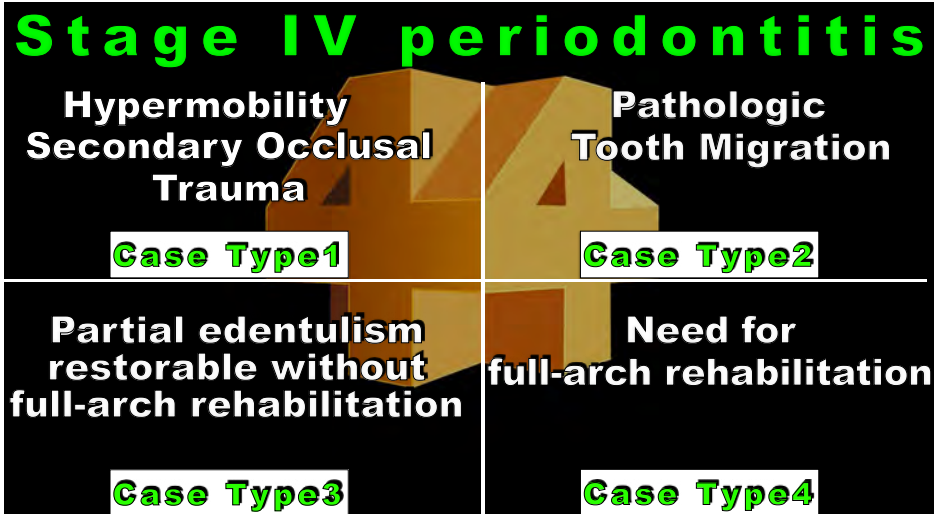
<sup>2</sup> Herrera D, et al. 2022. Opus cit

<sup>3</sup> Avila G, Galindo-Moreno P, Soehren S, Misch CE, Morelli T, Wang HL. *A novel decision-making process for tooth retention or extraction*. J Periodontol. 2009;80(3):476-91. DOI:10.1902/jop.2009.080454.

<sup>4</sup> Lundgren D, Rylander H, Laurell L. *To save or to extract, that is the question. Natural teeth or dental implants in periodontitis-susceptible patients: clinical decision-making and treatment strategies exemplified with patient case presentations*. Periodontol 2000. 2008;47:27-50. DOI:10.1111/j.1600-0757.2007.00239.x

<sup>5</sup> Carnevale G, Cairo F, Tonetti MS. (2007) *Long-term effects of supportive therapy in periodontal patients treated with fibre retention osseous resective surgery. II: tooth extractions during active and supportive therapy*. J Clin Periodontol. 2007;34:342-8. DOI:10.1111/j.1600-051X.2007.01052.x

- the integration of periodontal, orthodontic and implant therapies may be the best approach to successfully treat partially edentulous patients affected by stage IV periodontitis
- the patient's aesthetic needs should not be overestimated, as most are happy to keep their natural teeth
- it is important to remember that the role of the patient is a key factor for long-term success<sup>6</sup>

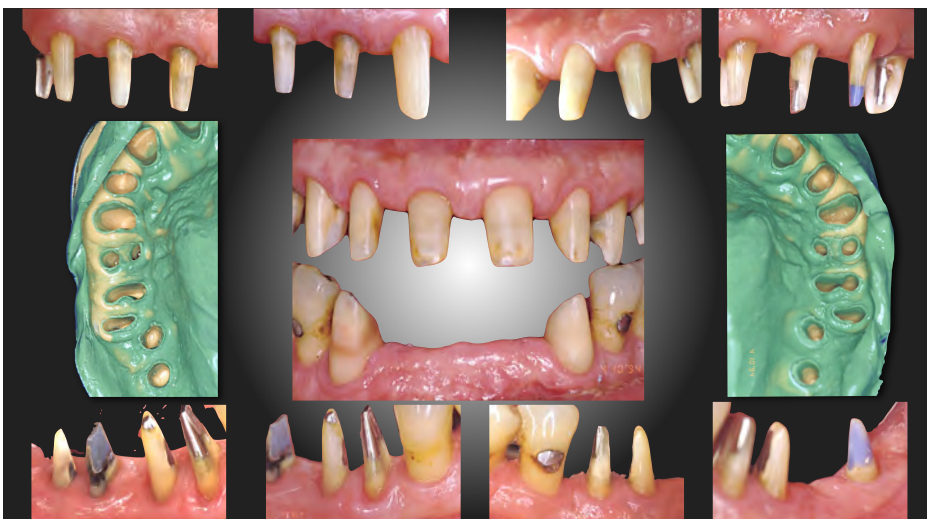

## Periodontal & Prosthetic Procedures



Periodontal  
Prosthesis

- To eliminate tooth/site periodontal risk factors
- To extract teeth if periodontal risk factors could not be completely eliminated (“strategic extractions”)
- To use the remaining teeth as prosthetic abutments for a fixed rehabilitation



<sup>6</sup> Sandberg HC, Fors UG. The HIDEF model-a straightforward dental health care model for prevention-based practice management. Swed Dent J. 2007;31(4):171-9. PMID: 18220220.

## Nicola Zitzmann

### How to handle patients with stage IV periodontitis: removable restorations

This presentation focused on treating patients with stage IV periodontitis with removable restorations. It covered the following topics:

- temporary removable restorations
- final removable dental prostheses (RDPs) or overdentures
- RDPs as an alternative after implant failure
- implants for support or retention

As the first speaker had explained, the rehabilitation requirements of patients with stage IV periodontitis are complex and can include replacing teeth, re-establishing masticatory function, and compensating for soft and hard tissue deficiencies.

During baseline examination, increased tooth mobility should not be applied as a decisive prognostic factor, because it is per se not pathologic.<sup>1</sup> At the time of periodontal treatment and elimination of inflammation, selective occlusal adjustments can be performed to reduce trauma from occlusion. In cases of increased tooth mobility and the need for a temporary interim prosthesis, an intraoral scan is more useful for establishing occlusal registration than a conventional impression. Particularly when anterior are missing or have to be extracted, a well designed temporary removable restoration can be used to cover the healing phase. These prostheses should have appropriate stability and occlusal rests to avoid gingival trauma. Temporary prostheses also allow restoration of the occlusal plane along with the vertical dimension in occlusion (VDO)<sup>2</sup>.

After the resolution of inflammation during the healing phase (stage two), implants can be placed (stage three at the earliest) to support a final overdenture to be installed in the last phase, based on the protocol set out by Herrera et al.<sup>3</sup>. Indications for a definitive RDP

or overdenture include the need for lip and cheek support from the dental flange; severe ridge defects requiring compensation from the denture base; a limited number of remaining teeth and/or teeth with a questionable prognosis; and patient factors such as limited ability to perform oral hygiene ability or financial limitations<sup>4</sup>.

When the tooth is intact, retention elements over teeth can take the form of a clasp or an adhesive attachment for aesthetic purposes. When a tooth needs to be crowned, a telescopic crown or a crown with a clasp can be used. In cases where there is coronal destruction, the options are a lab-designed root cap, or if there are financial constraints, a Dalbo Rotex or Ticap that is applied chairside. Implants are helpful as means of providing additional support and should provide retention with resilient attachments. All these options have to fulfil the requirements of retention, passivity, vertical support by occlusal rest, horizontal stabilisation and reciprocal effect<sup>5</sup>.

In high-risk patients with implant failures, switching from a fixed to a removable prosthesis is an option for avoiding additional surgical procedures. When additional support or retention is required in patients with remaining anterior teeth, posterior implants may be used, combined with a resilient retention system<sup>6</sup>.

To conclude, following diagnosis and tooth-by-tooth assessment of prognosis and restorability, a suitably designed temporary that includes occlusal rests should be provided during different steps of the periodontal therapy. In cases where soft tissue support is required, a definitive RDP will be the preferred treatment choice (ensuring the reciprocal effect). Implants should only be placed when risk factors have been eliminated or reduced. Resilient attachment systems are required when combining teeth and implants.

<sup>1</sup> Dommisch H, Walter C, Difio-Geisert J.C, Gintautė A, Jepsen S, Zitzmann NU. *Efficacy of tooth splinting and occlusal adjustment in patients with periodontitis exhibiting masticatory dysfunction: A systematic review*. J Clin Periodontol. 2022;49(S24):149–66. DOI:10.1111/jcpe.13563

<sup>2</sup> Zitzmann NU, Marinello CP. *Treatment plan for restoring the edentulous maxilla with implant-supported restorations: removable overdenture versus fixed partial denture design*. J Prosthet Dent. 1999;82(2):188–96. DOI:10.1016/s0022-3913(99)70155-1.

<sup>3</sup> Herrera et al. 2022. Opus cit.

<sup>4</sup> Zitzmann & Marinello, 1999. Opus cit.

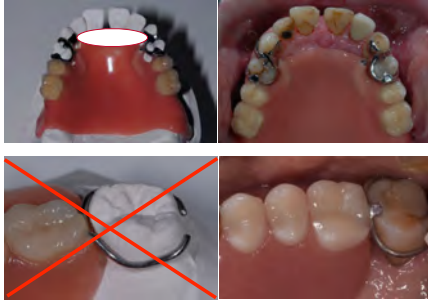
<sup>5</sup> Zitzmann NU, Rohner U, Weiger R, Krastl G. *When to choose which retention element to use for removable dental prostheses*. Int J Prosthodont. 2009;22:161–7. PMID: 19418863.

<sup>6</sup> Karakas-Stupar I, Zaugg LK, Zitzmann NU, Joda T, Wolfart S, Tuna T. *Clinical Protocol for Implant-Assisted Partial Removable Dental Prostheses in Kennedy Class I: A Case Report*. Prosthesis 2023;5(4):1002–10. DOI:10.3390/prosthesis5040069



## Temporary removable restorations

Design with sufficient stability: occlusal rests, no gingival trauma



## Final removable dental prostheses RDP

Removable partial denture RPD or overdenture OD

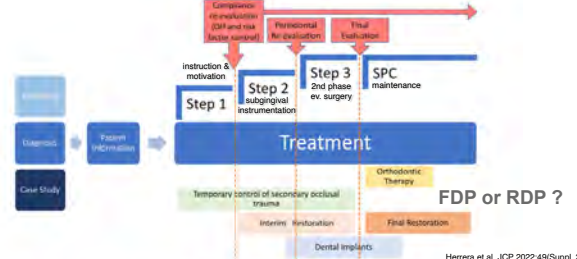


FIGURE 1 Visual description of timing/sequence of implementation of the adjunctive orthodontic/restorative treatment and the periodontal treatment (OHI, oral hygiene)

Herrera et al. JCP 2022;49(Suppl. 24):4-71

## Final removable dental prostheses RDP

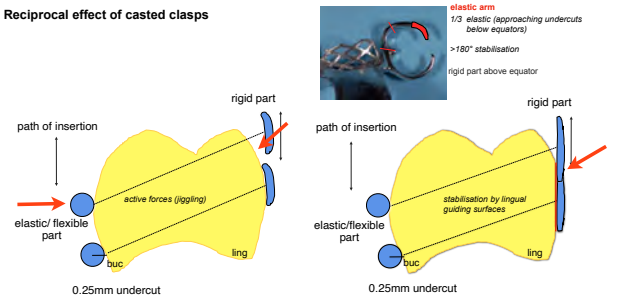
Which retention element for which tooth ?

element	coverage	requirements
clasp	RPD	intact tooth substance
adhesive attachment	RPD	ideal position (intra-/intermax) intact enamel
telescope	RPD	crown preparation required minor changes in tooth position
crown with clasp or extracoronal attachment	RPD	
root cap	overdenture/hybride	coronal tooth substance destroyed, max. flexibility
Dalbo Rotex/TiCap	overdenture/hybride	ditto with reduced prognosis
implant	overdenture	support or retention (resilient)

Zitzmann et al. UP 2009;22:161-7

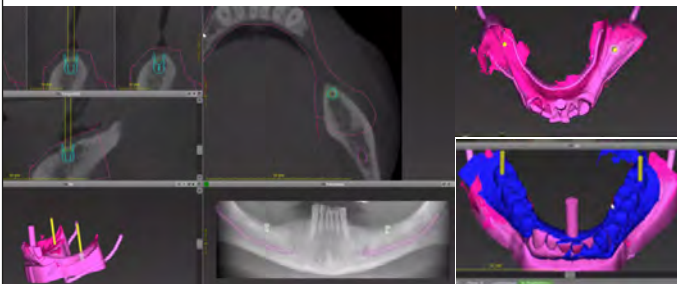
## Final removable partial denture RDP

Reciprocal effect of casted clasps



Zitzmann et al. UP 2009;22:161-7

## Implants for additional support or retention ?



Karakas-Stupar, Zaugg, Zitzmann, Joda, Wolfart, Tuna  
Case report from dual-center study. Prosthesis 2023;5:1002-10

# The frail patient: how to include patient perspectives

The first part of this session presented a detailed strategy for preventing phonetic complications that may arise following complete rehabilitation.

The second part focused on patient-reported outcome measures (PROMs). Although these are acknowledged as being key to treatment outcomes, including the patient's perspective in treatment is challenging in the case of the frail patient.

Both presentations looked at what makes patients feel and report that they 'are in good hands' when they visit their dentist – as opposed to having a poor experience.

The latest patient-centred care initiatives were also examined, with an analysis of the present level of care in nursing homes and the potential for enhancements.

## Najla Chebib

### Managing phonetics complications in implant dentistry

Audience-members were asked if they had had to deal with a patient with phonetic problems and their response was overwhelmingly yes. 100% had experienced these problems, and almost 40% had not have been able to solve them.

During speech, there is bidirectional feedback between the anatomical structures involved and the sound perceived by the brain, which the former if mispronunciation occurs.

The point of contact between the tongue and the floor of the mouth is called the point of articulation. The pronunciation of consonants is determined by the place of articulation, the vibration of the vocal cords, and the manner of articulation.

Making vowel sounds depends on the shape of the oral tract. The presence or absence of teeth also has implications for pronunciation of sounds.

In order to detect possible pathologies or impairments in pronunciation, phonetic tests can be carried out using standard words, and there are devices that measure the oral kinetics of the tongue and its relationship with the brain.

Each patient is unique and has specific psychomotor and adaptability characteristics that must be taken into account prior to treatment.

In cases involving rehabilitation with implants, PROMs take into account eating comfort, speech and aesthetics. PROM data indicates that patients are equally satisfied with both fixed prostheses and overdentures, although they report greater cleansability with the latter<sup>1</sup>, along with fewer phonation problems<sup>2</sup>.

In cases of severe atrophy, placing implants in the phonetic zone and encroaching into the palate should be avoided.

The first investigations into phonetics and full fixed reconstructions on implants in the maxilla, took place in 1992. They found that almost half of patients had pronunciation difficulties in the first 3 and 6 months, although these disappeared in the majority of patients when assessed at 3 years following treatment. However, 8% of patients stated that phonetic difficulties persisted even after 3 years<sup>3</sup>.

Concluding her review of the literature, the speaker noted that:

- there are typically more problems in the maxilla, especially with fixed reconstructions<sup>4</sup>
- the gap between the mucosa and the fixed prosthesis is thought to be the cause of speech errors
- components take up space and should never invade the phonetic zone

1 Duong HY, Rocuzzo A, Stähli A, Salvi GE, Lang NP, Sculean A. Oral health-related quality of life of patients rehabilitated with fixed and removable implant-supported dental prostheses. *Periodontol* 2000. 2022;88(1):201-37. DOI:10.1111/prd.12419

2 Zitzmann NU, Marinello CP. Treatment plan for restoring the edentulous maxilla with implant-supported restorations: removable overdenture versus fixed partial denture design. *J Prosthet Dent*. 1999;82(2):188-96. DOI:10.1016/s0022-3913(99)70155-1

3 Lundqvist S, Lohmander-Agerskov A, Haraldson T. Speech before and after treatment with bridges on osseointegrated implants in the edentulous upper jaw. *Clin Oral Implants Res*. 1992;3(2):57-62. DOI:10.1034/j.1600-0501.1992.030202.x

4 Heydecke G, McFarland DH, Feine JS, Lund JP. Speech with maxillary implant prostheses: ratings of articulation. *J Dent Res*. 2004;83(3):236-40. DOI:10.1177/154405910408300310

- it's important to understand and connect with patients, as it's their self-perception that can be more important than objective measurements of issues
- adaptation to new situations is generally possible, although the most persistent pronunciation problems are with the 's'

The speaker highlighted the following clinical tips to prevent pronunciation problems:

- good planning is essential, including discussion of design options with the patient and appropriate speech tests before the prosthesis is fabricated
- the planned implant screw holes should be as close as possible to the position of the natural teeth
- the space required for restorative components must be considered in the design, especially in the anterior areas of the jaws
- the interim phase is a good time to identify speech problems and correct them by adjusting the temporaries
- reinforcing the temporaries by increasing their thickness too much can cause temporary phonetic problems for the patient, especially if they encroach on the tongue space

Whether using provisionals or prototypes of the definitive prosthesis, all appropriate phonetic tests must be carried out to ensure the patient's pronunciation is correct. Once the contours have been checked to ensure they are suitable for correct pronunciation, they can be transferred to the laboratory via the intraoral scanner.

Speech problems frequently come from teeth situated in an excessively palatal position, or from overestimating the vertical dimension of occlusion.<sup>5</sup>

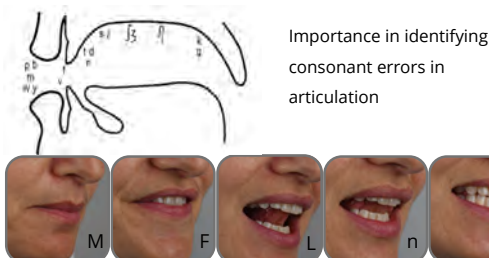
With maxillary overdentures, it's necessary to leave the palate free and create a smooth transition of around 20°–30° between the prosthesis and the palate. In the mandible, the bar must not intrude into the tongue area and should instead follow the contour of the jaw.

For fixed maxillary rehabilitations that are already in place, a decrease of up to 3mm in the palatal cuspid height in the premolar area will solve most phonetic problems<sup>6</sup>.

In conventional full dentures, an artificial incisal papilla can be created which forces the tongue into a lower position, enabling the 's' channel to be created. This channel has been represented with electropalatographic diagrams which illustrate the sagittal groove that is required in order to pronounce the 's' sound<sup>7</sup>.

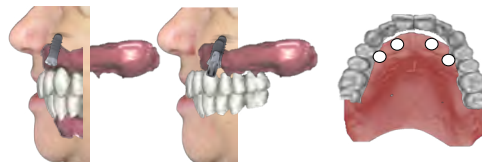
Palatograms can be obtained using powders (such as talcum powder or cocoa powder) to determine where material should be removed. Tissue conditioner or wax can be used for under-contoured areas to illustrate where additional material is required. These techniques can detect the support of the tongue during pronunciation and allow areas of excessive pressure (or, conversely, areas of excess space and lack of tongue support<sup>8</sup>) to be identified.

## 1-Manner of articulation



## 2-Patient case characteristics

Severe atrophy cases require a special attention as implants and their components are placed **right in the phonetic zone**.



<sup>5</sup> Giovannetti M, Casucci A, Casucci D, Mazzitelli C, Borracchini A. *Phonetic analysis and maxillary anterior tooth position: A pilot study on preliminary outcome*. Int Dent SA. 2011;11(5):32–9

<sup>6</sup> Collaert B, Van Dessel J, Konings M, Nackaerts O, Zink I, Slagmolen P, Jacobs R. *On Speech Problems with Fixed Restorations on Implants in the Edentulous Maxilla: Introduction of a Novel Management Concept*. Clin Implant Dent Relat Res. 2015;17 Suppl 2:e745–50. DOI:10.1111/cid.12309

<sup>7</sup> Bhat JT, Kumar N, Singh K, Tanvir H. *Phonetics in prosthodontics: its clinical implications in designing of prosthesis*. Int J Appl Dent Sci. 2021;7(2):84–93. DOI:10.22271/oral.2021.v7.i2b.1193

<sup>8</sup> Lagdive SB, Shah RJ, Sindha DV, Hadiya K, Sabugar N. *Palatogram: A Guide to Customised, Functional Palatal Contour*. J Clin Diagn Res. 2017;11(7):ZD06–ZD09. DOI:10.7860/JCDR/2017/27417.10208

# Gerry McKenna

## Patient perspective

A progressive increase in life expectancy is leading to an increasing number of frail older adults who require care at home or in residential homes. By contrast, many healthcare staff are not trained in the oral care of older patients.

According to the 2018 ITI consensus conference, the survival of dental implants in the over-75s is similar to that of younger patients at 1 and 5 years.

A variety of factors and scenarios may reduce implant survival. These include systemic diseases, such as poorly controlled diabetes, particularly where HbA2c levels are above 8%. Among patients being treated for cancer, those receiving head and neck radiotherapy or intravenous administration of bisphosphonates had reduced implant survival rates<sup>1</sup>.

A survey of the audience showed that 45% used PROMs in their private practice. When audience-members were asked which aspects of clinical care they felt were most important to their patients, quality of life and restoring function scored highest. By contrast, much of the data in the scientific literature focuses on clinical outcomes.

The speaker referred to the 'disability paradox'<sup>2</sup>, which shows that there are differences between how patients perceive their health and well-being and their objective health status and disability, which is often worse than their perception. Because patients' assessment of their health often differs significantly from the opinion of healthcare professionals, carrying out patient assessments of healthcare interventions is very important.

By focusing on patient-centred care<sup>3</sup>, we can improve the patient experience, with particular benefits for older patients who have greater levels of dependency. There is widespread agreement on the need to consider patients' own assessments of their oral health status and their views of treatment outcomes.

Patient-reported outcomes (PROs) enable outcomes to be scored directly by the patient without the intervention of the clinician. The impact of oral health on the patient's day-to-day life or 'quality of life' is termed Oral Health-Related Quality of Life or OHRQoL. PROs also evaluate patients' satisfaction with their oral health status.

Patient-reported outcome measures (PROMs) are used to measure PROs. Condition-specific PROMs, such as those for oral health, measure patients' perceptions of a specific disease or health problem.

The 2023 ITI consensus conference included an investigation of patient benefits following implant treatment in partially and fully edentulous patients. Following analysis of a number of systematic reviews, it was concluded that edentulous patients experience significant benefits both in quality of life and oral function following treatment with dental implants<sup>4</sup>.

The speaker referred to some specific consensus findings relating to PROMs and implant treatments among fully edentulous patients. He noted that similar satisfaction levels are associated with overdentures and fixed prostheses. In terms of oral function, both implant-supported fixed prostheses and removable prostheses improve mastication in all clinical situations, regardless of the antagonist, when compared to conventional full dentures.

The ITI consensus conference also made recommendations for future research, including gathering dental PROMs (dPROMs) in a way that is methodical and comparable, such as via the Oral Health Impact Profile (OHIP). Future studies and trials should also include appropriate parameters of oral function as outcome measures<sup>5</sup>.

The concept of co-production builds on the benefits of gathering PROM data by facilitating collaborations between researchers, different medical specialties and patients. It focuses on partnership working and shared leadership, and shifts service design away from a 'top down' model<sup>6</sup>.

One example is the TOPIC study (Improving the Oral Health of Older People in Care Homes: a Feasibility Study) which aims to align oral care in care homes with the 2018 National Institute for Health and Care Excellence (NICE) practice guidelines through collaboration with care home staff and family members<sup>7</sup>. For more information visit <https://topic-oralhealth.co.uk>.

Other research projects, which use discrete choice experiments, have assessed the preferences of older patients for various approaches to dental care. Different preferences were found in different countries. For example, older patients in Switzerland and the UK had a strong preference for continuity of care within a

1 Schimmel M, Srinivasan M, McKenna G, Müller F. Effect of advanced age and/or systemic medical conditions on dental implant survival: A systematic review and meta-analysis. Clin Oral Implants Res. 2018;29 Suppl 16:311-30. DOI:10.1111/clr.13288

2 Albrecht GL, Devlieger PJ. The disability paradox: high quality of life against all odds. Soc Sci Med. 1999;48(8):977-88. DOI:10.1016/S0277-9536(98)00411-0

3 McGrath C, Lam O, Lang N. An evidence-based review of patient-reported outcome measures in dental implant research among dentate subjects. J Clin Periodontol. 2012;39 Suppl 12:193-201. DOI:10.1111/j.1600-051X.2011.01841.x

4 Abou-Ayash S, Fonseca M, Pieralli S, Reissmann DR. Treatment effect of implant-supported fixed complete dentures and implant overdentures on patient-reported outcomes: A systematic review and meta-analysis. Clin Oral Implants Res. 2023;34 Suppl 26:177-95. DOI:10.1111/clr.14065

5 Srinivasan M, Kamnoedboon P, Angst L, Müller F. Oral function in completely edentulous patients rehabilitated with implant-supported dental prostheses: A systematic review and meta-analysis. Clin Oral Implants Res. 2023;34 Suppl 26:196-239. DOI:10.1111/clr.14068

6 Schimmel M, Araujo M, Abou-Ayash S, et al. Group 4 ITI Consensus Report: Patient benefits following implant treatment in partially and fully edentulous patients. Clin Oral Implants Res. 2023;34 Suppl 26:257-65. DOI:10.1111/clr.14145

7 Brocklehurst PR, McKenna G, Schimmel M, et al. How do we incorporate patient views into the design of healthcare services for older people: a discussion paper. BMC Oral Health. 2018;18(1):61. DOI:10.1186/s12903-018-0513-7

7 Langley J, Wassall R, Geddis-Regan A, et al. Putting guidelines into practice: Using co-design to develop a complex intervention based on NG48 to enable care staff to provide daily oral care to older people living in care homes. Gerodontology. 2023;40(1):112-26. DOI:10.1111/ger.12629

family dental practice, while in Greece older patients wanted dental treatment provided in their own home<sup>8</sup>.

Financial preferences have also been investigated, including patients' willingness to pay higher prices for different prosthetic solutions for the edentulous jaw. A sample of 26 older patients in Japan reported greater benefit from and a strong preference for an overdenture compared to a full denture, but less willingness to pay for its high cost<sup>9</sup>.

Finally, the concept of 'core outcome sets' (COSs) was discussed. This describes an agreed set of outcomes that should be measured and reported in all trials relating to a specific condition. The Core Outcome Measures in Effectiveness Trials (COMET) initiative develops and applies agreed standardised sets of outcomes across various health-related fields. A recent paper, which was contributed to by members of the EAO, set out a minimum set of data needed

to measure treatment outcomes in implant dentistry and defined the Implant Dentistry Core Outcome Set and Measurement (ID-COSM)<sup>10</sup>. ID-COSM includes clinical aspects such as phonetics and oral function, along with PROs such as quality of life and patient satisfaction.

In conclusion, implants are a successful treatment option for replacing missing teeth in older patients. However, treatment planning should include future considerations, such as implant maintenance, before adults become dependent on others for oral care.

PROs should be considered alongside clinical outcome measures when planning and assessing treatment, and research should ideally be co-produced with patients and relevant stakeholders.

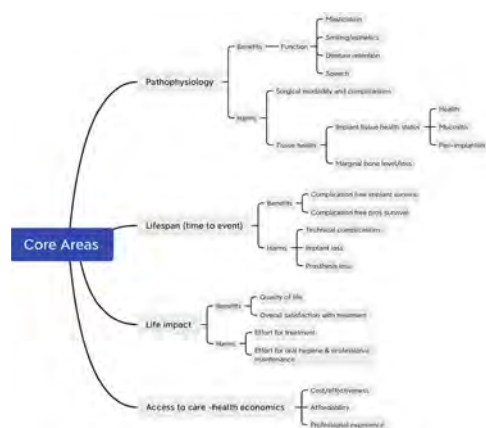Future research should include dental patient reported outcomes (dPROs) and measure function in relation to the ID-COSM.

## Condition specific dPROMs for oral health

Authors	Name of measure
Cushing <i>et al.</i> , 1986	Social Impacts of Dental Disease
Atchison and Dolan, 1990	Geriatric Oral Health Assessment Index
Strauss and Hunt, 1993	Dental Impact Profile
Slade and Spencer, 1994	Oral Health Impact Profile
Locker and Miller, 1994	Subjective Oral Health Status Indicators
Leao and Sheiham, 1996	Dental Impact on Daily Living
Adulyanont and Sheiham, 1997	Oral Impacts on Daily Performances
McGrath and Bedi, 2000	OH-QoL UK



## The Implant Dentistry Core Outcome Set and Measurement (ID-COSM) international consensus



<sup>8</sup> Chebib N, Holmes E, Maniewicz S, et al. Exploring preferences of older adults for dental services: A pilot multi-national discrete choice experiment. *Gerodontology*. 2023 Jun 13. DOI:10.1111/ger.12696

<sup>9</sup> Tada S, Kanazawa M, Miyayasu A, Iwaki M, Srinivasan M, Minakuchi S, McKenna G. Patient preferences for different tooth replacement strategies for the edentulous mandible: A willingness-to-pay analysis. *J Prosthodont Res*. 2021;65(4):535-40. dDOI: 10.2186/jpr.JPR\_D\_20\_00170

<sup>10</sup> Tonetti MS, Sanz M, Avila-Ortiz G, et al. Relevant domains, core outcome sets and measurements for implant dentistry clinical trials: The Implant Dentistry Core Outcome Set and Measurement (ID-COSM) international consensus report. *J Clin Periodontol*. 2023;50 Suppl 25:5-21. DOI:10.1111/jcpe.13808



# Treatment concept in the posterior region: timing concepts

This session looked at whether immediate implant placement and immediate implant loading really work in the posterior region. It provided practical guidelines for these two important treatment approaches.

## Gary Finnelle

### Immediate versus conventional implant placement in molar sites

The presenter began by stating that in his private practice in Paris, more than 50% of the teeth he replaced were first molars. Audience-members were then asked to indicate which of the three implant placement protocols, as defined by the 2004 ITI consensus, were their usual options. The answers were as follows:

- immediate placement, day 0, at the time of extraction: 20%
- conventional placement, more than three months after extraction: 60%
- socket preservation performed, then implant placed four to six months later: 20%

The problem with both conventional and delayed placement is that 30–50% of the buccal bone plate resorbs within 6 months of extraction<sup>1</sup>. As well as this reduction in bone quantity, the quality of the bone and the keratinised soft tissue can also be affected. Furthermore, resorption is not entirely predictable, which can sometimes make it difficult to place the implant. In summary, the delayed procedure involves:

- two operations
- a treatment duration of at least six months
- a compromise in tissue volume and quality
- unpredictable reabsorption
- frequent need for invasive GBR procedures

Socket preservation is another well-studied option, but the speaker explained that he didn't typically choose it because:

- it requires two operations
- it involves a treatment duration of more than nine months
- it includes invasive GBR closure techniques
- there is an uncertain postoperative recovery
- there is still has some tissue contour compromise

The third option is immediate implant placement (IIP). Although IIP has been more commonly used in the aesthetic zone, there is increasing evidence to support its use in the posterior zone:

- 99% cumulative survival rate in nine studies involving 1,013 implants followed for two to five years<sup>2</sup>
- 97.8% cumulative survival rate in periapically infected sites in a study that followed up 418 implants followed for an average of five years<sup>3</sup>

In conclusion, IIP appears to be an ideal option because:

- it has a similar survival rate to implant placement in healed sites
- it only requires one operation
- the total treatment time is three to four months
- it is a flapless procedure
- it is associated with reduced post-operative recovery and patient morbidity

However, IIP also presents two anatomical challenges: achieving primary stability and primary closure. Achieving primary closure to prevent bone resorption using tissue displacement techniques leads to additional complications and loss of keratinised tissue. Instead, the speaker recommended a rigid and passive prosthetic closure of the healing space with a customised healing abutment whose critical profile closely fits the soft tissue margin. This protects the extraction socket and prevents tissue collapse. The procedure is called the socket seal abutment technique (SSA) and is a minimally invasive transition strategy that links surgery and prosthetics and preserves tissue contours until the final crown is placed<sup>4</sup>.

The conventional workflow consists of the following steps:

- atraumatic extraction with root separation
- intraseptal drilling
- immediate implant placement

1 Araújo MG, Sukekava F, Wennström JL, Lindhe J. Ridge alterations following implant placement in fresh extraction sockets: an experimental study in the dog. *J Clin Periodontol*. 2005;32(6):645-52. DOI:10.1111/j.1600-051X.2005.00726.x.

2 Atieh MA, Payne AG, Duncan WJ, de Silva RK, Cullinan MP. Immediate placement or immediate restoration/loading of single implants for molar tooth replacement: a systematic review and meta-analysis. *Int J Oral Maxillofac Implants*. 2010;25(2):401-15. PMID: 20369102.

3 Fugazzotto P. A retrospective analysis of immediately placed implants in 418 sites exhibiting periapical pathology: results and clinical considerations. *Int J Oral Maxillofac Implants*. 2012;27(1):194-202. PMID: 22299097.

4 Finnelle G, Lee SJ. Guided Immediate Implant Placement with Wound Closure by Computer-Aided Design/Computer-Assisted Manufacture Sealing Socket Abutment: Case Report. *Int J Oral Maxillofac Implants*. 2017;32(2):e63-e67. DOI:10.11607/jomi.4770.

- filling with biomaterial
- protecting the site with a customised healing abutment developed from a composite framework
- no flap, no incision, no suture, no membrane

Published data created by superimposition of pre- and postoperative CBCT scans showed ten times less one-year bone resorption for SSA than for alveolar preservation<sup>5</sup>. Bone is maintained by stabilising the blood clot and biomaterials in a confined space, which is one of the principles of GBR<sup>6</sup>. Two additional studies by the same team compared soft tissue contour changes by superimposing pre- and postoperative STL digital models. These showed only 1mm of vertical and horizontal tissue shrinkage after two years<sup>7</sup>.

There are now clear guidelines on the ideal abutment for the immediate placement protocol:

- to simplify the technique, an anatomical abutment should be customisable, requiring minimal manipulation. It should also be possible to scan it without removing it
- to improve the patient's experience, it should be as biocompatible as possible;
- to preserve tissue volume, the abutment's shape should optimise the emergence profile and its surface should be highly polished

All these features have been incorporated into Biotech Dental's SSA Gingival Fit abutment, which comes in three different shapes and can be easily adapted to each case by adding a little flowable composite to the margins.

To conclude, the speaker asked 'where are the limits?' of the immediate approach for molars:

- lack of primary stability
- inability to achieve passive closure
- presence of buccal or lingual bone dehiscence
- loss of attachment in adjacent teeth
- lack of keratinised tissue

By contrast, emerging evidence from the 'immediate, plus SSA' protocol suggests that it has a number of significant benefits, including:

- treatment that only lasts three months and only requires three appointments
- an uneventful postoperative period
- tissue stability
- reduced costs

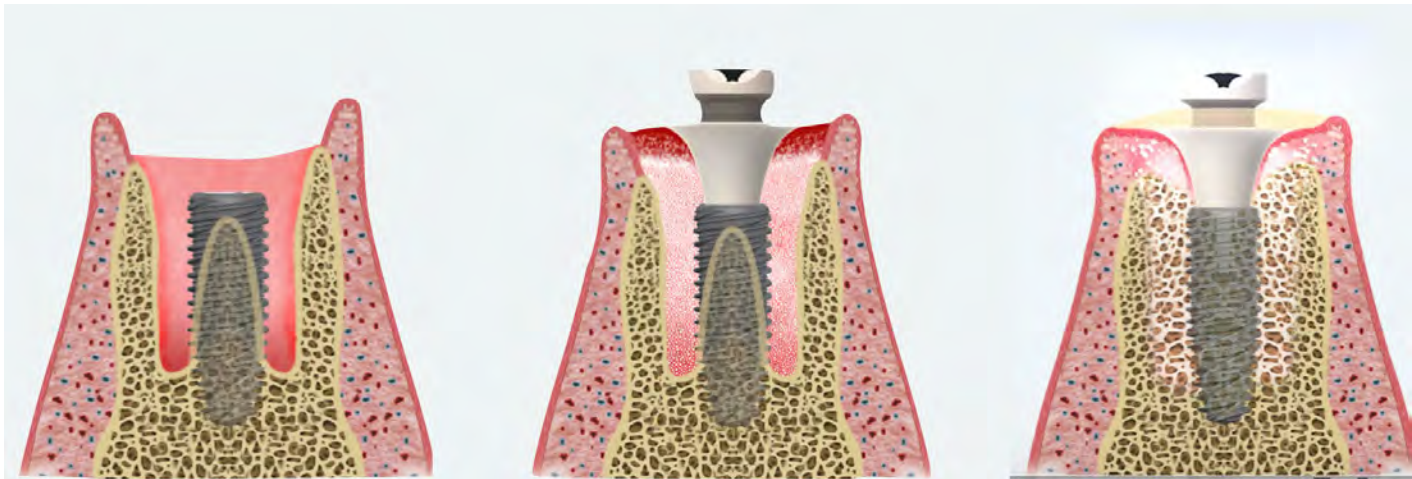<sup>5</sup> Alexopoulou M, Lambert F, Knafo B, Popelut A, Vandenberghe B, Finelle G. *Immediate implant in the posterior region combined with alveolar ridge preservation and sealing socket abutment: A retrospective 3D radiographic analysis*. Clin Implant Dent Relat Res. 2021;23(1):61-72. DOI:10.1111/cid.12974.

<sup>6</sup> Retzepi M, Donos N. *Guided Bone Regeneration: biological principle and therapeutic applications*. Clin Oral Implants Res. 2010;21(6):567-76. DOI:10.1111/j.1600-0501.2010.01922.x.

Wang HL, Boyapati L. "PASS" principles for predictable bone regeneration. Implant Dent. 2006;15(1):8-17. DOI:10.1097/01.id.0000204762.39826.0f.

<sup>7</sup> Finelle G, Popelut A, Knafo B, Martin IS. *Sealing Socket Abutments (SSAs) in Molar Immediate Implants with a Digitalized CAD/CAM Protocol: Soft Tissue Contour Changes and Radiographic Outcomes After 2 Years*. Int J Periodontics Restorative Dent. 2021;41(2):235-44. DOI:10.11607/prd.4579.

Lilet R, Desiron M, Finelle G, Lecloux G, Seidel L, Lambert F. *Immediate implant placement combining socket seal abutment and peri-implant socket filling: A prospective case series*. Clin Oral Implants Res. 2022;33(1):33-44. DOI:10.1111/clr.13852.



# SSA

Sealing Socket Abutment

Finelle G., Lee S. Computer assisted immediate implant placement and wound closure: CAD-CAM sealing socket abutment technique. A case report - JOMI April 2017

Immediate implant  
*Lazzara RJ., 1989*

Regeneration space  
*Gomez-Meda „2021*

Dr. Francois Vigouroux

Biological  
Bone integrity  
*Straight & Slim*

Transitional  
Tissue integrity  
*Concave*

Prosthetic  
Cervical contour integrity  
*Anatomical & convexe*

C  
B  
E

z  
o  
n  
e

González-Martin O., 2021

## Stefan Vandeweghe

# Immediate versus conventional loading of implants in the posterior region

Immediate loading (IL) is one of the most widely documented topics in the scientific literature, and occurred in 14.3% of papers published on implant dentistry in the twenty-first century<sup>1</sup>. Although many papers on immediate loading in the anterior zone continue to be published, in the last five years there has been a decline in published research on the posterior zone.

A recent systematic review of IL showed that the evidence differs between the anterior and posterior zones<sup>2</sup>. In the posterior maxilla routine treatment involves conventional placement and delayed loading, and IL is insufficiently documented for immediate or delayed placement. In the posterior mandible, IL is clinically documented for delayed placement. However, there is insufficient clinical evidence to support IL for immediate placement, even when primary stability is enhanced by under-preparation or the use of wide-diameter implants.

According to the ITI consensus<sup>3</sup>, for single implants in healed sites:

- IL is predictable for anterior and premolar regions, although aesthetically demanding cases should be approached with caution and treated by experienced clinicians
- In the mandibular molar region, IL and early loading are also predictable and recommended where clinical benefits are identified
- In the maxillary molar region, the low amount of data does not allow the general recommendation of IL or early loading, and conventional protocol should be the choice

The procedure is predictable in the posterior zone for healed extended sites with multiple implants, albeit with limited clinical benefits. In the anterior zone, however, it should only be performed by experienced clinicians and reserved for carefully reserved cases. Criteria should include high primary stability, an absence of the need for substantial bone augmentation, factor related to implant design, occlusal factors, patient habits, good systemic health and the experience level of the clinician.

## Implant design

Regarding implant design, a randomised clinical trial in the posterior mandible comparing tapered versus cylindrical implants concluded that IL performance was similar in both groups. However, primary stability was better in the tapered group<sup>4</sup>. A prospective clinical study reached the same conclusion<sup>5</sup>. This effect may be due to greater compression exerted on the insertion by the conical shape than by the cylindrical one.

## Implant diameter and length

A 2009 study concluded that increasing the diameter and/or length of the implant better supports the forces that are loaded on to the surrounding bone and reduces stress on the alveolar crest, with diameter having a more pronounced effect than length<sup>6</sup>.

Wide implants were compared in IL versus conventional loading and no significant differences were observed<sup>7</sup>. However, in a clinical study with 8mm and 9mm diameters, success rates were 83.3% and 66.7% for the delayed and immediate placement groups respectively, irrespective of the loading protocol followed<sup>8</sup>. The authors concluded that excessive compressive stress could have been a reason for early failures. Another study on IL with a novo wide-body implant obtained a mean survival rate of 95.7% and stable bone conditions after a year, irrespective of loading or surgical protocol<sup>9</sup>.

An extensive meta-analysis including 2,461 implants concluded that there is no more risk of failure with short implants, < 10mm, compared with conventional implants under IL<sup>10</sup>.

Another study involving IL on pairs of 6.5mm extra short implants that were supporting a fixed partial prosthesis found no difference in the clinical results compared with conventional implants, provided the implants were splinted<sup>11</sup>.

- 1 Pommer B, Valkova V, Ubaidha Maheen C, Fürhauser L, Rausch-Fan X, Seeman R. *Scientific Interests of 21st Century Clinical Oral Implant Research: Topical Trend Analysis*. Clin Implant Dent Relat Res. 2016;18(4):850-6. DOI:10.1111/cid.12371.
- 2 Zhou W, Gallucci GO, Chen S, Buser D, Hamilton A. *Placement and Loading Protocols for Single Implants in Different Locations: A Systematic Review*. Int J Oral Maxillofac Implants. 2021;36(4):e72-e89. DOI:10.11607/jomi.8750.
- 3 Gallucci GO, Benic GI, Eckert SE, Papaspyridakos P, Schimmel M, Schrott A, Weber HP. *Consensus statements and clinical recommendations for implant loading protocols*. Int J Oral Maxillofac Implants. 2014;29 Suppl:287-90. DOI:10.11607/jomi.2013.g4.
- 4 Kim YY, Song YW, Kim MJ, Cha JK, Park JM, Kim JH, Jung UW. *Immediate loading of fixed partial prostheses reconstructed using either tapered or straight implants in the posterior area: A randomized clinical trial*. Clin Implant Dent Relat Res. 2021;23(5):703-15. DOI:10.1111/cid.13039.
- 5 Lozano-Carrascal N, Salomó-Coll O, Gilbert-Cerdà M, Farré-Pagés N, Gargallo-Albiol J, Hernández-Alfaro F. *Effect of implant macro-design on primary stability: A prospective clinical study*. Med Oral Patol Oral Cir Bucal. 2016;21(2):e214-21. DOI:10.4317/medoral.21024.
- 6 Ding X, Liao SH, Zhu XH, Zhang XH, Zhang L. *Effect of diameter and length on stress distribution of the alveolar crest around immediate loading implants*. Clin Implant Dent Relat Res. 2009;11(4):279-87. DOI:10.1111/j.1708-8208.2008.00124.x.
- 7 Schincaglia GP, Marzola R, Giovanni GF, Chiara CS, Scotti R. *Replacement of mandibular molars with single-unit restorations supported by wide-body implants: immediate versus delayed loading. A randomized controlled study*. Int J Oral Maxillofac Implants. 2008;23(3):474-80. PMID: 18700371.
- 8 Atieh MA, Alsabeeha NH, Duncan WJ, de Silva RK, Cullinan MP, Schwass D, Payne AG. *Immediate single implant restorations in mandibular molar extraction sockets: a controlled clinical trial*. Clin Oral Implants Res. 2013;24(5):484-96. DOI:10.1111/j.1600-0501.2011.02415.x.
- 9 Vandeweghe S, Ackermann A, Bronner J, Hattingh A, Tschakaloff A, De Bruyn H. *A retrospective, multicenter study on a novo wide-body implant for posterior regions*. Clin Implant Dent Relat Res. 2012;14(2):281-92. DOI:10.1111/j.1708-8208.2009.00253.x.
- 10 Wu H, Shi Q, Huang Y, Chang P, Huo N, Jiang Y, Wang J. *Failure Risk of Short Dental Implants Under Immediate Loading: A Meta-Analysis*. J Prosthodont. 2021;30(7):569-80. DOI:10.1111/jopr.13376.
- 11 Anitua E, Flores C, Flores J, Alkhraisat MH. *Clinical Effectiveness of 6.5-mm-Long Implants to Support Two-Implant Fixed Prostheses in Premolar-Molar Region: The Influence of Immediate Loading and the Length of Splinting Implant*. J Prosthodont. 2019;28(2):e688-e93. DOI:10.1111/jopr.12761.



## Sinus graft

A clinical case series involving IL of implants protruding into the sinus after membrane lifting without biomaterials concluded that it is a predictable procedure, provided that insertion torque was no less than 20N<sup>12</sup>.

A histological study in humans using immediately loaded micro-implants biopsied after two months concluded that a bone graft does not increase primary stability, and that primary stability provided by the residual bone is the only reliable factor in terms of loading capacity<sup>13</sup>.

## Implant surface

Since current implant designs with moderately rough surfaces improve the osseointegration, they also increase loading capacity. This conclusion was reached by a 9-year follow-up clinical trial comparing IL on TiUnite and machined surface implants in the posterior mandible. The survival rate of TiUnite implants was superior, especially in smokers and in cases with poor bone quality<sup>14</sup>.

## Other biological factors

A review has estimated that the critical micromotion threshold for osseointegration is 50–150 microns<sup>15</sup>. The authors recommended splinting to prevent deleterious micromotion. The same article signalled the well-known concept from orthopaedics that early weight-bearing is beneficial for fracture healing. Therefore, small micro movements produced by IL can be considered a positive factor for osseointegration, providing they are within the tolerated limit.

There is controversy about the optimal insertion torque for achieving maximum bone-to-implant contact without excessive strain that damages the crest. A literature review found a lack of evidence, and the authors concluded that an optimal bone response to IL may not only be determined not only by primary stability of the implant, but also by optimised load transfer through an appropriate implant design and surface<sup>16</sup>.

Insertion torque does not always strictly determine the degree of micromotion. This conclusion was reached in a study comparing

different implant macro designs. The authors demonstrated that adding cutting edges may decrease insertion torque and, at the same time, lead to less micromotion<sup>17</sup>.

A meta-analysis on single implants in the posterior mandible found no significant differences between conventional loading and IL in terms of survival, marginal bone loss or occurrence of complications<sup>18</sup>. The authors emphasised that non-functional immediate loading may perform better than functional IL and that implant shape and surface may play an important role, especially in type IV bone.

The factors that make IL more likely to be successful have been highlighted in literature reviews looking at immediately loaded implants in the posterior zone. Achieving good primary stability is a pre-requisite for successful immediate or early loading procedures. This is positively influenced by under-preparation, implant macro shape (tapered designs with apical threads), micro rough surface characteristics and rigid splinting. For immediate loading, an insertion torque  $\geq 30\text{N}$  or ( $\geq 20\text{N}$  when splinted) should be achieved. Occlusion control is another essential consideration, with the literature emphasising that there should only be light centric contact and no lateral excursive contacts. In addition, detecting fractures of the provisional as soon as they occur is critical for preventing overload.

In the posterior jaw, IL is well documented for delayed placement, but there is a lack of evidence in immediate placement cases. Turning to patient satisfaction, it has not been clearly demonstrated whether the different loading protocols have an influence and what their cost-effectiveness might be<sup>19</sup>.

A recent clinical study detected more tactile sensitivity in immediately loaded single implants opposing to natural teeth. The cause of this remains unknown<sup>20</sup>.

In a multi-centre study, soft tissue volume was better preserved when an anatomical healing abutment was placed alongside immediate implants. The authors noted an increased failure rate when a provisional restoration was placed instead of the shaped abutment<sup>21</sup>.

- 12 Cricchio G, Imburgia M, Sennerby L, Lundgren S. *Immediate loading of implants placed simultaneously with sinus membrane elevation in the posterior atrophic maxilla: a two-year follow-up study on 10 patients*. Clin Implant Dent Relat Res. 2014;16(4):609-17. DOI:10.1111/cid.12035.
- 13 Browaeys H, Vandeweghe S, Johansson CB, Jimbo R, Deschepper E, De Bruyn H. *The histological evaluation of osseointegration of surface enhanced microimplants immediately loaded in conjunction with sinuslifting in humans*. Clin Oral Implants Res. 2013;24(1):36-44. DOI:10.1111/j.1600-0501.2011.02398.x.
- 14 Rocci A, Rocci M, Rocci C, Scoccia A, Gargari M, Martignoni M, Gottlow J, Sennerby L. *Immediate loading of Brånemark system TiUnite and machined-surface implants in the posterior mandible, part II: a randomized open-ended 9-year follow-up clinical trial*. Int J Oral Maxillofac Implants. 2013;28(3):891-5. DOI:10.11607/jomi.2397.
- 15 Szmukler-Moncler S, Salama H, Reingewirtz Y, Dubrille JH. *Timing of loading and effect of micromotion on bone-dental implant interface: review of experimental literature*. J Biomed Mater Res. 1998;43(2):192-203. DOI:10.1002/(sici)1097-4636(199822)43:2<192::aid-jbm14>3.0.co;2-k.
- 16 Duyck J, Vandamme K. *The effect of loading on peri-implant bone: a critical review of the literature*. J Oral Rehabil. 2014;41(10):783-94. DOI:10.1111/joor.12195.
- 17 Freitas AC Jr, Bonfante EA, Giro G, Janal MN, Coelho PG. *The effect of implant design on insertion torque and immediate micromotion*. Clin Oral Implant Res. 2012;23:113-8. DOI:10.1111/j.1600-0501.2010.02142.x.
- 18 Moraschini V, Porto Barboza E. *Immediate versus conventional loaded single implants in the posterior mandible: a meta-analysis of randomized controlled trials*. Int J Oral Maxillofac Surg. 2016;45(1):85-92. DOI:10.1016/j.ijom.2015.07.014.
- 19 Rocuzzo M, Aglietta M, Cordaro L. *Implant loading protocols for partially edentulous maxillary posterior sites*. Int J Oral Maxillofac Implants. 2009;24 Suppl:147-57. PMID: 19885442. De Bruyn H, Raes S, Ostman PO, Cosyn J. *Immediate loading in partially and completely edentulous jaws: a review of the literature with clinical guidelines*. Periodontol 2000. 2014;66(1):153-87. DOI:10.1111/prd.12040. Atieh et al. IJOMI 2010; opus cit.
- 20 Deepika K, Bhatnagar A, Singh A, Soni R. *Evaluation of active tactile sensibility in a single-tooth implant opposing a natural tooth with either an immediate or delayed functional loading protocol: A parallel design clinical study*. J Prosthet Dent. 2023;S0022-3913(22)00752-1. DOI:10.1016/j.prosdent.2022.11.019.
- 21 Amato F, Amato G, Campriani S, Contessi M, D'Amato F, Fiorentini AG, Polara G, Spedicato GA. *The Role of Different Healing Abutment Sizes in Tissue Volume Preservation of Molar Sockets After Immediate Tooth Extraction and Implant Placement: A Multicenter Clinical Study*. Int J Oral Maxillofac Implants. 2022;37(5):891-904. DOI:10.11607/jomi.9607.



## Conclusions

- the outcome of immediate or delayed loaded posterior implants is comparable
- the outcome of immediate loaded posterior or anterior implants is comparable
- there is a lack of data on immediate placement in conjunction with immediate loading
- there is a lack of data on the soft tissue response
- key factors are the implant morphology and primary stability
- clinicians should be experienced and consider the cost-benefit of immediate loading

# Treatment concepts posterior region: sinus lift reloaded

This session looked at two different approaches to the same problem: the management of limited residual height in the posterior maxilla using a lateral open or transcrestal sinus lift. The session compared and discussed the indications and limitations of both approaches.

## David Nisand

### Battle of concepts: lateral open sinus lift

In line with the available scientific evidence, the decision-making process in the posterior maxilla should be based on the residual bone height (RBH). As short implants represent a less expensive, faster and less invasive solution than a sinus lift<sup>1</sup>, the presentation focused on cases with RBH of < 6mm:

- RBH ≤ 2mm: *lateral open sinus lift*
- RBH > 2 mm and < 6 mm: *the battle zone*
- RBH ≥ 6mm: *short implants*

With RBH ≤ 2mm an open sinus lift is usually chosen because of its low complication rate<sup>2</sup>. Use of CBCT and knowledge of the sinus anatomy is crucial when performing an open lateral sinus lift.

There is no specific recommendation on the type of the graft material to be used, but placing a resorbable collagen membrane is advised, followed by replacement of the bone trapdoor if possible, since this is associated with higher implant survival rate and a lower risk of graft displacement<sup>3</sup>.

The speaker recommended extreme caution with regard to concomitant implant placement, due to the difficulties in obtaining achieve a sufficient primary stability, and the challenge of achieving an ideal prosthetic position in such advanced crestal bone

atrophies. While immediate or delayed implant placement has a similar success rate, the risk of complications decreases when the residual bone height is more than 3mm<sup>4</sup>.

The most frequent complication is a perforation of the membrane, with a frequency of around 20–25%<sup>5</sup>. The occurrence of a perforation is strongly associated with the residual bone height, the anatomy of the sinus floor, the thickness of the buccal sinus wall, the presence of intrasinus septae, the type of the surgical approach and the experience of the oral surgeon. It is particularly associated with the presence of a bony septum, which is estimated to be present in 30% of sinus floors<sup>6</sup>. Depending on the size of the membrane perforation and its location, solutions include using a resorbable membrane or suturing the Schneider membrane.

Another common complication of the lateral approach is bleeding of the superior alveolar artery. To prevent this, the osteotomy can often be located coronally to the artery<sup>7</sup>. The speaker added that in his opinion the use of piezosurgery drastically decreases the risk of a haemorrhage.

Postoperative infection of the sinus is relatively rare, occurring in 2–5% of cases, and may be related to contamination via a sinus membrane perforation or infected graft material. Any infection

- 1 Nisand D, Renouard F. *Short implant in limited bone volume*. Periodontol 2000. 2014;66(1):72-96. DOI:10.1111/prd.12053.
- 2 Pjetursson BE, Tan WC, Zvahlen M, Lang NP. *A systematic review of the success of sinus floor elevation and survival of implants inserted in combination with sinus floor elevation*. J Clin Periodontol. 2008;35(8 Suppl):216-40. DOI:10.1111/j.1600-051X.2008.01272.x.  
Shi JY, Gu YX, Zhuang LF, Lai HC. *Survival of Implants Using the Osteotome Technique With or Without Grafting in the Posterior Maxilla: A Systematic Review*. Int J Oral Maxillofac Implants. 2016;31(5):1077-88. DOI:10.11607/jomi.4321.  
Ragucci GM, Elnayef B, Suárez-López Del Amo F, Wang HL, Hernández-Alfaro F, Gargallo-Albiol J. *Influence of exposing dental implants into the sinus cavity on survival and complications rate: a systematic review*. Int J Implant Dent. 2019;5(1):6. DOI:10.1186/s40729-019-0157-7.  
Testori T, Weinstein T, Taschieri S, Wallace SS. *Risk factors in lateral window sinus elevation surgery*. Periodontol 2000. 2019;81(1):91-123. DOI:10.1111/prd.12286.
- 3 Del Fabbro M, Wallace SS, Testori T. *Long-term implant survival in the grafted maxillary sinus: a systematic review*. Int J Periodontics Restorative Dent. 2013;33(6):773-83. DOI:10.11607/prd.1288.
- 4 Raghoobar GM, Onclin P, Boven GC, Vissink A, Meijer HJA. *Long-term effectiveness of maxillary sinus floor augmentation: A systematic review and meta-analysis*. J Clin Periodontol. 2019;46 Suppl 21:307-18. DOI:10.1111/jcpe.13055.
- 5 Nolan PJ, Freeman K, Kraut RA. *Correlation between Schneiderian membrane perforation and sinus lift graft outcome: a retrospective evaluation of 359 augmented sinus*. J Oral Maxillofac Surg. 2014;72(1):47-52. DOI:10.1016/j.joms.2013.07.020.  
Moreno Vazquez JC, Gonzalez de Rivera AS, Gil HS, Mifsut RS. *Complication rate in 200 consecutive sinus lift procedures: guidelines for prevention and treatment*. J Oral Maxillofac Surg. 2014;72(5):892-901. DOI:10.1016/j.joms.2013.11.023.
- 6 Van den Bergh JP, ten Bruggenkate GM, Disch FJ, Tuinzing DB. *Anatomical aspects of sinus floor elevations*. Clin Oral Implants Res. 2000;11(3):256-65. DOI:10.1034/j.1600-0501.2000.011003256.x.
- 7 Rosano G, Taschieri S, Gaudy JF, Weinstein T, Del Fabbro M. *Maxillary sinus vascular anatomy and its relation to sinus lift surgery*. Clin Oral Implants Res. 2011;22(7):711-5. DOI:10.1111/j.1600-0501.2010.02045.x.

should be treated as soon as possible. The speaker presented the following protocol for this complication<sup>8</sup>:

1. Restitution and/or change of antibiotic therapy
2. Insertion of drain with antibiotic therapy
3. Partial or complete debridement of the graft material
4. Total debridement of the graft and sinus cavity via an oral approach and/or functional endoscopic sinus surgery

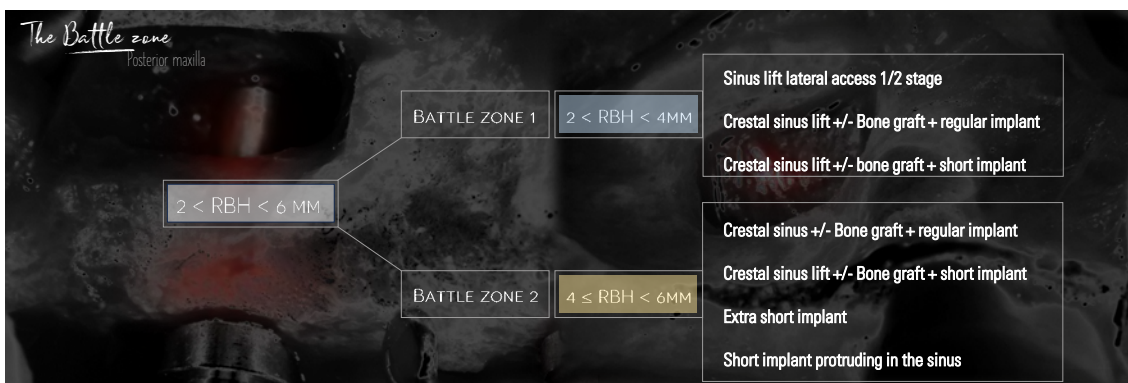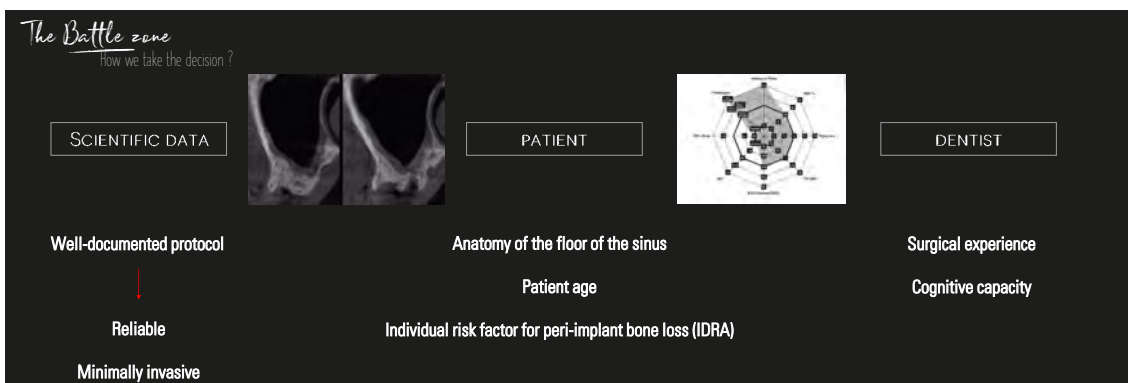
The speaker went on to subdivide the 'battle zone' into two categories, based on the RBH, and described the treatment options for each of them:

- battle zone 1: RBH > 2mm and < 4mm
  - » lateral sinus lift across one to two stages (simultaneous or delayed placement)

- » crestal sinus lift +/- bone graft + regular implant
- » crestal sinus lift +/- bone graft + short implant

- battle zone 2: RBH > 4mm and < 6mm
  - » crestal sinus lift +/- bone graft + regular implant
  - » crestal sinus lift +/- bone graft + short implant
  - » extra short implant (4–5mm length)
  - » short implant protruding into the sinus

Outside the battle zone, in those clinical cases with a RBH ≥ 6mm, the alternative is the use of short implants, which have shown very similar results to standard implants, whether in single crowns or in bridges. Short implants may represent a survival problem if progressive marginal bone loss arises. However, the evidence shows that they have a similar physiological marginal bone loss to standard implants<sup>9</sup>.



<sup>8</sup> Testori T, et al. 2019. Opus cit.

Schlund M, Meeus J, Politis C, Ferri J. Management of sinus graft infection-a systematic review. Int J Oral Maxillofac Surg. 2022;51(5):690-8. DOI:10.1016/j.ijom.2021.09.007.

<sup>9</sup> Thoma DS, Haas R, Sporniak-Tutak K, Garcia A, Taylor TD, Hammerle CHF. Randomized controlled multicentre study comparing short dental implants (6 mm) versus longer dental implants (11-15 mm) in combination with sinus floor elevation procedures: 5-Year data. J Clin Periodontol. 2018;45(12):1465-74. DOI:10.1111/jcpe.13025.

Grunau O, Terheyden H. Lateral augmentation of the sinus floor followed by regular implants versus short implants in the vertically deficient posterior maxilla: a systematic review and timewise meta-analysis of randomized studies. Int J Oral Maxillofac Surg. 2023;52(7):813-24. DOI:10.1016/j.ijom.2022.11.015.

## Roberto Farina

### Battle of concepts: transalveolar/crestal sinus lift

This discussion compared transalveolar and transcrestal approaches to sinus lifts, and again focused on the height of remaining bone in the posterior maxilla. When residual bone height is between 1mm and 8mm, the range of treatment modalities is as follows (although specific options require minimum amounts of bone, as described below):

- short implants
- transalveolar/transcrestal sinus floor elevation (tSFE)
- lateral sinus floor elevation (ISFE)

In the systematic review by Vetromilla et al. in 2021<sup>1</sup>, short implants were found to have the same survival rate as standard implants placed after a sinus lift. They were associated with fewer biological complications than the sinus lift option, but more prosthetic complications. The speaker concluded that when there is sufficient RBH to place a short implant (between 6mm and 8mm) this should be considered the first choice for treatment.

When there is 6 mm or less of RBH, the choice is between tSFE or ISFE, although contrary to popular opinion the preferred option is not solely determined by the RBH. A doctoral thesis prepared at the University of Ferrara illustrated that the indications for the tSFE technique have been expanding over time, and it has been successfully used to address increasingly atrophic ridges while obtaining more and more vertical bone regeneration<sup>2</sup>.

A recent systematic review demonstrated that tSFE is effective in terms of survival and bone gain, and that it is a less invasive option from the patient's point of view (PROMs)<sup>3</sup> compared to ISFE. Responding to this, the moderators made an interesting comment that one of the main limitations of systematic reviews in this field is to consider average RBH, which may result in them comparing clinical situations that would not necessarily be treated in the same way.

A recent publication looked at levels of invasiveness in the different tSFE approaches. Invasiveness was defined not only with regard to the degree of pain and morbidity, but also in relation to the amount of medication required; the aesthetic impact; chair-time and costs of both the treatment and any complications that may occur. Among

the different tSFE techniques, complications were almost entirely related to procedures that led to the fracture of the sinus floor with manual instruments, such as osteotomes or hand mallets. No differences in vertical bone gain and implant survival were found between manual tSFE based on manual (i.e. osteotomes) versus powered instruments.<sup>4</sup>

With respect to chair time, approaches that use powered instruments were the fastest. Furthermore, standardised sequences that include a trephine drill for implant bed preparation, along with the option to control pressure (such as screwable osteotomes) and /or instrument excursion (such as drills with stop devices) are the most beneficial for this technique.<sup>4</sup>

When RBH is between 3mm and 6mm, and using a standardised sequence of instruments adapted to predetermined ridge heights and with stop devices, tSFE has been shown to result in similar reconstructive outcome<sup>5</sup>, more tolerable postoperative course<sup>6</sup>, and lower surgery-related costs<sup>7</sup> compared to ISFE.

The speaker presented a re-analysis of a previous RCT (Farina et al. 2018) comparing tSFE and ISFE.<sup>8</sup> In the range between 4mm and 6mm, it concludes that while there are no significant differences in radiographic results for bone gain, marginal bone loss, membrane perforation rate, pain levels or even total analgesic dose, there are differences in favour of tSFE with respect to chair time, prevalence of inflammation, bruising and nasal discharge and/or bleeding, and surgery costs (biomaterials and anaesthesia).

In the 3–4 mm range the results are less clear. The majority of the variables presented no differences between techniques, except in postoperative pain in days 0 and 1, and nasal bruising. The former was significantly higher in tSFE while the latter more frequent in ISFE.<sup>17</sup>

In this specific range, other variables may come into play such as the bucco-palatal width of the sinus cavity. An inverse correlation between this dimension and new bone formation was found in a proof-of-concept prospective cohort study<sup>9</sup>. In a retrospective study of 430 patients treated with tSFE, a higher rate of

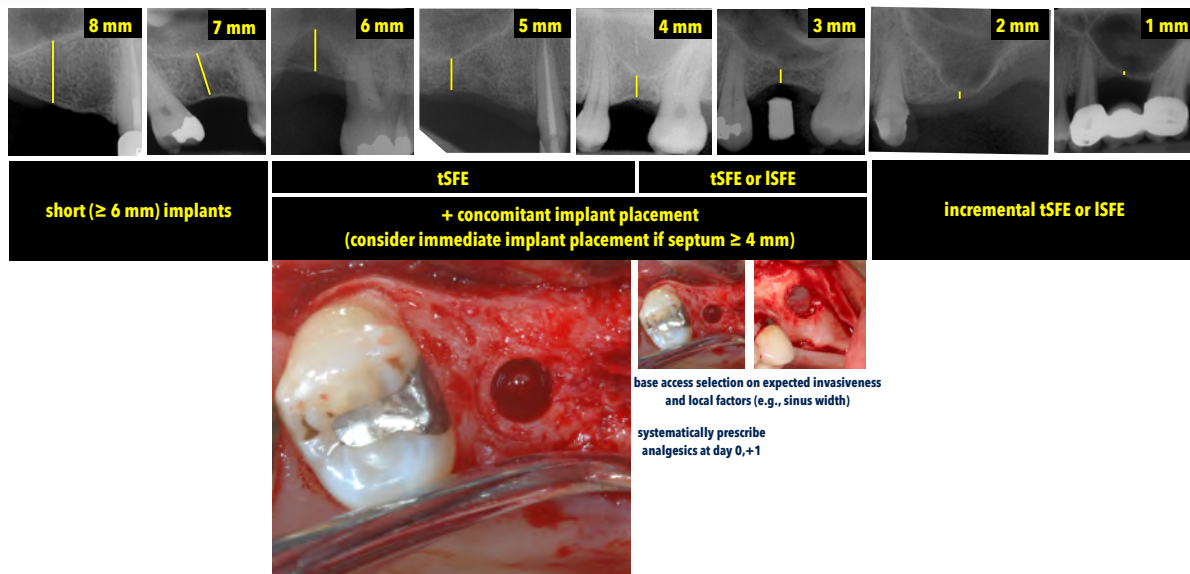
- 1 Vetromilla BM, Mazzetti T, Pereira-Cenci T. *Short versus standard implants associated with sinus floor elevation: An umbrella review of meta-analyses of multiple outcomes.* J Prosthet Dent. 2021;126(4):503-11. DOI:10.1016/j.prosdent.2020.08.002.
- 2 Pietrobello, D. (supervisor: prof. L. Trombelli). *Elevazione del pavimento del seno mascellare con accesso transcrestale: revisione sistematica della letteratura.* Graduation Thesis. University of Ferrara, Italy (a.y. 2016/17)
- 3 Shi S, Han L, Su J, Guo J, Yu F, Zhang W. *Clinical efficacy of transcrestal sinus floor augmentation, in comparison with lateral approach, in sites with residual bone height ≤6 mm: A systematic review and meta-analysis.* Clin Oral Implants Res. 2023;34(11):1151-75. DOI:10.1111/clr.14155.
- 4 Farina R, Franzini C, Trombelli L, Simonelli A. *Minimal invasiveness in the transcrestal elevation of the maxillary sinus floor: A systematic review.* Periodontol 2000. 2023;91(1):145-66. DOI:10.1111/prd.12464.
- 5 Farina R, Franceschetti G, Travaglini D, Consolo U, Minenna L, Schincaglia GP, Riccardi O, Bandieri A, Maietti E, Trombelli L. *Radiographic outcomes of transcrestal and lateral sinus floor elevation: One-year results of a bi-center, parallel-arm randomized trial.* Clin Oral Implants Res. 2019 Sep;30(9):910-919. doi: 10.1111/clr.13497. Epub 2019 Jul 10.
- 6 Farina R, Franceschetti G, Travaglini D, Consolo U, Minenna L, Schincaglia GP, Riccardi O, Bandieri A, Maietti E, Trombelli L. *Morbidity following transcrestal and lateral sinus floor elevation: A randomized trial.* J Clin Periodontol. 2018;45(9):1128-39. DOI:10.1111/jcpe.12985.
- 7 Farina R, Simonelli A, Franceschetti G, Travaglini D, Consolo U, Minenna L, Schincaglia GP, Riccardi O, Bandieri A, Trombelli L. *Implant-supported rehabilitation following transcrestal and lateral sinus floor elevation: analysis of costs and quality of life from a bicenter, parallel-arm randomized trial.* Minerva Dent Oral Sci. 2022;71(1):16-24. DOI:10.23736/S2724-6329.21.04539-3
- 8 Farina R, Franzini C, Minenna L, Trombelli L, Simonelli A. *Effectiveness, Morbidity, and Costs of Transcrestal and Lateral Sinus Floor Elevation at Sites with Different Residual Bone Heights: A Re-Analysis of Data from a Parallel-Arm Randomized Trial.* Int J Oral Maxillofac Implants. 2023 Dec 12;38(6):1123-1138.
- 9 Lombardi T, Stacchi C, Berton F, Traini T, Torelli L, Di Lenarda R. *Influence of Maxillary Sinus Width on New Bone Formation After Transcrestal Sinus Floor Elevation: A Proof-of-Concept Prospective Cohort Study.* Implant Dent. 2017;26(2):209-16. DOI:10.1097/ID.0000000000000554.

membrane perforation and early implant failure was also reported in wider sinuses<sup>10</sup>.

The tSFE technique can also be successfully applied in immediate implant placement after maxillary molar extraction, with no differences in terms of membrane perforation, implant survival and patient satisfaction compared with tSFE combined with the delayed approach. In such cases, an intraradicular septum height of at least 4mm should be considered.<sup>11</sup>

Finally, where RBH is between 1mm and 2mm, the speaker emphasised that the technique should be adapted to the anatomy of the sinus. He presented an incremental tSFE technique executed in two surgeries<sup>12</sup>. An initial tSFE is performed to augment the bone, then the implant is placed four months later during a second procedure. During both procedures, a sequential system of drills is used with predetermined stop devices based on the required working length.

## Evidence-based indications to tSFE/ISFE according to residual bone height



## Conclusive remarks

**tSFE should be considered as a valid option for the implant-supported rehabilitation of posterior maxillary sites with residual bone height (RBH)  $\leq 6$  mm;**

**In order to minimize invasiveness, the technique to perform tSFE should privilege powered instruments available as a standardized sequence, to be adapted on predetermined RBH and including the possibility to control pressure and/or instrument excursion to fracture of the sinus floor.**

**Transalveolar approach with immediate implant placement can also be considered for molar sites with a  $\geq 4$  mm high septum;**

**When performed according to the principles of minimal invasiveness:**

- tSFE should be preferred to lateral sinus floor elevation at sites with RBH  $\geq 4$  mm and  $\leq 6$  mm due to lower chair time, more tolerable postoperative course and more favorable surgery-related costs;
- at sites RBH  $\geq 3$  mm and  $< 4$  mm, tSFE should be preferably performed under favorable local conditions (e.g., narrow sinus), and should be accompanied by systematic prescription of analgesics at days 0, +1;

**For RBH  $\geq 1$  and  $< 3$  mm, several tSFE techniques (including incremental tSFE with delayed implant placement) were proposed, but their efficacy and indication is presently not known.**



<sup>10</sup> Stacchi C, Bernardello F, Spinato S, Mura R, Perelli M, Lombardi T, Troiano G, Canullo L. Intraoperative complications and early implant failure after transcrestal sinus floor elevation with residual bone height  $\leq 5$  mm: A retrospective multicenter study. Clin Oral Implants Res. 2022;33(8):783-91. DOI:10.1111/clr.13959.

<sup>11</sup> Liu H, Liu R, Wang M, Yang J. Immediate implant placement combined with maxillary sinus floor elevation utilizing the transalveolar approach and nonsubmerged healing for failing teeth in the maxillary molar area: A randomized controlled trial clinical study with one-year follow-up. Clin Implant Dent Relat Res. 2019;21(3):462-72. DOI:10.1111/cid.12783.

<sup>12</sup> Trombelli L, Franceschetti G, Trisi P, Farina R. Incremental, transcrestal sinus floor elevation with a minimally invasive technique in the rehabilitation of severe maxillary atrophy. Clinical and histological findings from a proof-of-concept case series. J Oral Maxillofac Surg. 2015;73(5):861-88. DOI:10.1016/j.joms.2014.12.009.



# The frail patient: how to reduce treatment morbidity

- We are encountering an increasing number of frail patients in our clinics. How can we provide treatment that reduces the risk of harm and is minimally invasive?
- Furthermore, how can we simplify prosthetic solutions for frail patients, including those who are partially or fully edentulous?

This session described ways of achieving acceptable outcomes with low-complexity, low-morbidity treatments.

## Nadja Nänni

### Partially dentate: implants or conventional restoration

The speaker began by talking about what constituted a frail patient, noting that such a patient might be elderly and systemically compromised, but could also be younger or even juvenile. She presented a range of cases focusing on the clinical steps required for either implant placement or reconstruction on teeth (using a prosthetic approach) in partially dentate frail patients.

Regarding the placement of dental implants, two options were presented:

1. **Ridge preservation and late implant placement<sup>1</sup>.** As a step-by-step approach, this option gives the tissues time to heal and is simpler because it involves two non-complex interventions. It is associated with low patient morbidity, but longer treatment times and increased materials costs. A randomised study concluded that clinicians reported the same difficulties with tooth extraction, but easier flap elevation, implant placement and wound closure in the ridge preservation late implant group when compared with spontaneous healing and early implant placement<sup>2</sup>.
2. **Immediate implant placement.** This requires a single complex intervention, but involves shorter treatment times and results in low morbidity. Compared with the first option, it has improved cost and time efficiency<sup>3</sup>.

With regards to prosthetic approaches, a further two options were recommended:

1. **The use of pink ceramics.** This is particularly useful in frail patients, as it allows the avoidance of complex surgical interventions. Even if a perfect aesthetic result is not achieved, it is an approach that is worthy of consideration.
2. **Resin-bonded bridges.** A Maryland fixed provisional attached to the neighbouring teeth to seal the socket and allow tissues to heal can be a solution for provisionalisation. Following healing, a single-retainer resin-bonded bridge can be used as the final prosthesis in the anterior region. However, there is an important issue with resin-bonded bridges: what happens to the pontic site over time? The soft tissue contour has excellent stability over 10 years and reported survival rates for zirconia single-retainer resin-bonded bridges in the anterior region are between 98.2% and 100% <sup>4</sup>.

<sup>1</sup> Avila-Ortiz G, Chambrone L, Vignoletti F. *Effect of alveolar ridge preservation interventions following tooth extraction: A systematic review and meta-analysis*. J Clin Periodontol. 2019;46 Suppl 21:195-223. DOI:10.1111/jcpe.13057

<sup>2</sup> Thoma DS, et al. *A multicenter randomized controlled study comparing early implant placement to alveolar ridge preservation and late implant placement for single tooth replacement*. In preparation.

<sup>3</sup> Cosyn J, et al. *The effectiveness of immediate implant placement for single tooth replacement compared to delayed implant placement: A systematic review and meta-analysis*. J Clin Periodontol. 2019;46(Suppl 21): 224-41.

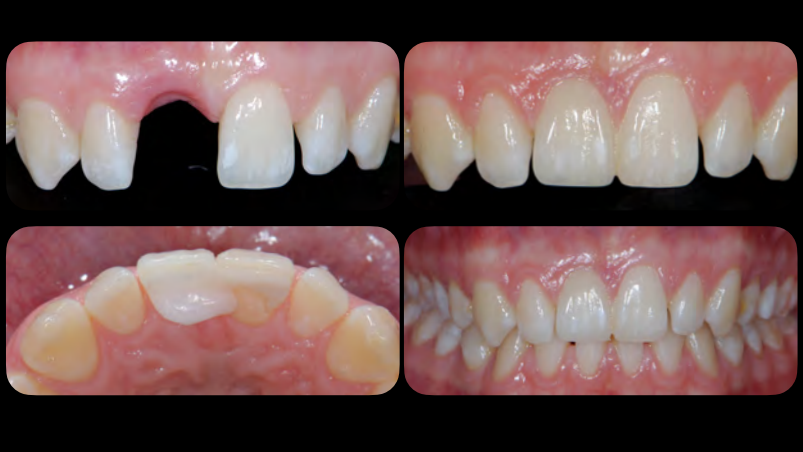
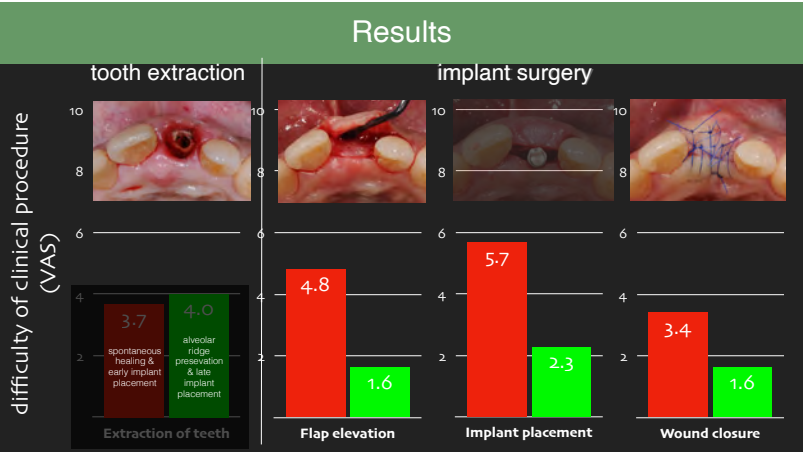
<sup>4</sup> Naenni N, et al. *Resin-bonded fixed dental prostheses with zirconia ceramic single retainers show high survival rates and minimal tissue changes after a mean of 10 years of service*. Int J Prosthodont 2020;33(5):503-12

### Ridge Preservation & Late Implant Placement

- Two Interventions
- Simple Approach
- Low Morbidity

### Immediate Implant Placement

- One Intervention
- Complex Approach
- Shorter Treatment Time



## Nicole Passia

# The edentulous frail patient: how to minimise invasiveness

267 million people worldwide were edentulous in 2017. In Europe, the estimated proportion of edentulous patients in the 65–74 year old age group (many of whom represent frail patients) is between 2.7% and 26.7%.

Frail edentulous patients often also have complex medical conditions, along with functional and/or cognitive impairments, and a reduced ability to adapt to new prostheses, along with reduced autonomy.

The least invasive treatment for edentulous patients is a complete denture, but this is not a comfortable option, especially in the mandible. For patients who have an edentulous lower jaw, implants are recommended, although placing multiple implants may be unacceptably invasive for frail patients.


When considering dental implants in frail edentulous patients, the goal is to reduce the surgical risks by minimising the invasiveness of the treatment, and this can be achieved using three strategies:

1. **Avoiding augmentation procedures by reducing the implant length.** Short implants can be used to support overdentures. This approach is safe with a significantly lower prevalence of prosthetic complications on removable prostheses compared with implant-supported fixed prostheses<sup>1</sup>.
2. **Shortening the healing period by reducing the implant diameter.** Narrow diameter implants (category 1 or mini-implants: <2.5 mm; category 2: 2.5–3.3 mm; category 3: 3.3–3.5 mm) can be considered for supporting definitive complete mandibular dentures<sup>2</sup>, although narrow diameter implants have better long-term predictability than mini-implants<sup>3</sup>. The success rate of narrow diameter implants in the maxilla is lower than in the mandible.
3. **Reducing the overall treatment time (as few appointments as possible) by reducing the number of implants.** In the maxilla, the placement of 2 or 3 implants for the retention of a removable prosthesis was studied, but led to poor results. However, in the lower jaw, 1 implant with a conventional loading protocol (loading after 3 months) using the existing adapted prosthesis of the patient as the definitive is a valid treatment option.

The edentulous patient - How to minimize invasiveness

The frail edentulous patients - what might we have to consider?

- Complex medical conditions
- Functional and/or cognitive impairment
- Reduced ability to adapt to new prostheses
- Reduced autonomy



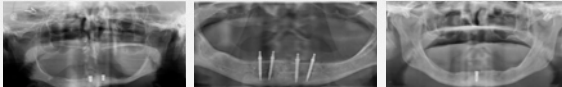
Schimmel M, Müller E, Suter V, Buser D. Implants for elderly patients. Periodontol 2000 2017;73:238-40.  
Müller F. Interventions for edentate elders—what is the evidence? Gerodontology 2014;31 (Suppl 1):44-51.

The edentulous patient - How to minimize invasiveness

Implants for frail edentulous patients

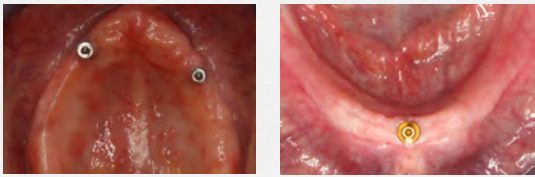
Goal: Reducing the surgical risks by minimising the invasiveness of the treatment.

- Avoiding augmentation procedures
- Shortening the healing period
- Reducing the overall treatment time
- Reducing the implant length
- Reducing the implant diameter
- Reducing the number of implants



The edentulous patient - How to minimize invasiveness

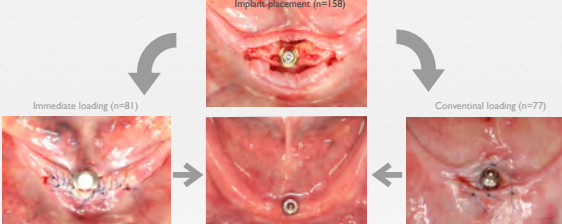
Reducing the number of implants



Passia N, Kern M. Erforderliche Anzahl von Implantaten für eine abnehmbare Versorgung im zahnlosen Kiefer: wissen kompakt 2020;14:155-9.

The edentulous patient - How to minimize invasiveness

Single dental implant retained mandibular complete dentures - Influence of the loading protocol(RCT)



Implant placement (n=158)

Immediate loading (n=81)

Conventional loading (n=77)

1. Pauletti P, et al. *Fixed and removable full-arch restorations supported by short ( $\leq 8$  mm) dental implants in the mandible: a systematic review and meta-analysis.* Int J Oral Maxillofac Implants 2019;34(4):873-85.
2. Jung RE, et al., *Group 1 ITI Consensus Report: the influence of implant length and design and medications on clinical and patient-reported outcomes.* Clin Oral Implants Res 2018;29(Suppl. 16):69-77.
3. Marcello-Machado RM, et al. *Mini-implants and narrow diameter implants as mandibular overdenture retainers: A systematic review and meta-analysis of clinical and radiographic outcomes.* J Oral Rehabil 2018;45(2):161-83.

# Big data and artificial intelligence: the future in implant dentistry

Big data is the generation and storage of enormous amounts of data, that, once processed, can pave the way for many new practical applications that are relevant to our daily lives. The combination of artificial intelligence and big data has the potential to enhance many processes. AI is often perceived as a threat, but when applied optimally it offers huge opportunities to enhance human capabilities.

Healthcare is one of the most promising application areas for AI, and many clinical decision support systems have already been developed. This session looked at how big data and AI are affecting our dental practice today, and what their advantages and disadvantages are.

## Andreas Dengel

### The future of digital data: an AI perspective to medicine

The machine learning process is based on aggregating multiple channels of information from a wide variety of sources. In the case of models for classifying and predicting diseases, these data sources can include biological, experimental, environmental, wearable and clinical data. These data are filtered and processed using appropriate algorithms to build models for understanding, categorising and predicting diseases.

However, in the so-called end-to-end approach, intermediate steps are no longer necessary because deep neural networks can directly process the data and build the models. For example, quantitative image analysis, which combines big data with deep learning, is growing exponentially.

#### AI in microscopy

Compared with conventional fluorescence staining microscopy, deep neural image analysis of unstained, label-free images under phase contrast microscopes, while still subject to limitations, is non-invasive, faster, cheaper and allows longer study periods.

Computer vision algorithms can segment, identify and classify objects in a field of view. To do this, they need to be trained on large image collections. In the case of the EVICAN dataset, the quality of the images was inadequate to carry out analysis by AI, but by adding and creating additional images scientists were able to build the LIVECell<sup>1</sup> data set. This has made it possible to automate the analysis of data in EVICAN, despite its poor quality. Thus trained systems can detect and count cells with high accuracy.

#### AI in skin diagnosis

AI applications are helping to assess images of skin lesions, despite their wide variation, with a diagnostic accuracy comparable

to that of dermatologists<sup>2,3</sup>. Skin lesions have historically been scored using a seven-feature algorithm for the ABCDE rule, both of which involve subjective assessment. Deep neural networks (XAI system) can do this better, provided they are trained with a large data set that is combined with feature maps plus individual classifiers for visual concepts along with corresponding labels. The neural network for this system was not explicitly trained on skin lesion concepts. Instead, it used photos of animals to, for example, learn that a picture was more likely to show a zebra than a tiger, combined with a textile dataset to enable learning of pattern types. These could then be abstracted to concepts that could be applied in order to differentiate other types of source material. In this way, deep neural networks learn a hierarchical structure from different feature-abstracted properties of whole objects, as in face recognition, working progressively from elementary inputs to complex outputs. ExAID<sup>4</sup> works in a similar way, and is now sufficiently developed to provide a second opinion for specialists and explain its decisions at the same time.

#### Exchanging data

Research requires access to and sharing of data. The European Health Data Space (EHDS) will enable this sharing of data while respecting ethical issues. However, many questions need to be answered in order to enable the sharing and use of data in a way that is both practical and ethical.

AI is helping us to identify and capitalise on previously unknown relationships between pieces of data. In doing so, it facilitates disease identification and medical decision-making. Its greatest potential lies in its ability to act as an 'intellectual amplifier'

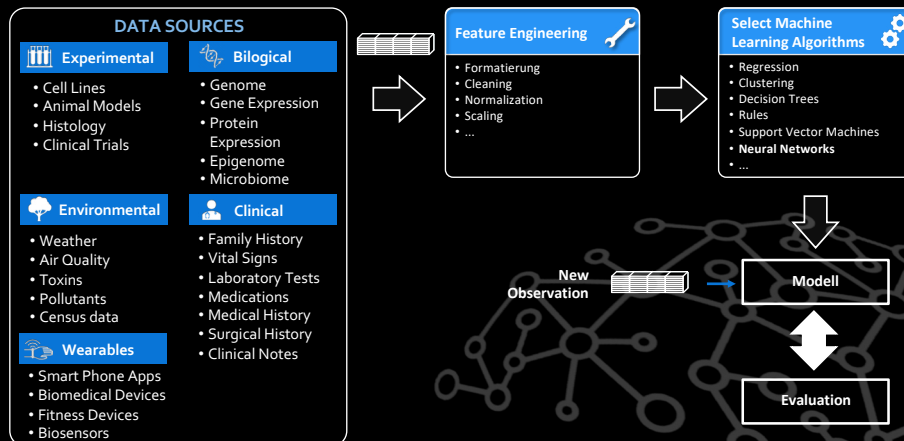
<sup>1</sup> C. Edlund, T. R. Jackson, N. Khalid, N. Bevan, T. Dale, A. Dengel, S. Ahmed, J. Trygg, and R. Sjörgen, *LIVECELL – A Large-Scale dataset for Label-Free Live Cell Segmentation*, Nature Methods, Springer Publ. (2021), doi: 10.1038/s41592-021-01249-6.

<sup>2</sup> Esteve A, Kuprel B, Novoa RA, et al. *Dermatologist-level classification of skin cancer with deep neural networks*. Nature. 2017;542(7639):115-8. DOI:10.1038/nature21056

<sup>3</sup> A. Lucieri, M. N. Bajwa, S. A. Braun, M. I. Malik, A. Dengel, and S. Ahmed, *ExAID: A Multimodal Explanation Framework for Computer-Aided Diagnosis of Skin Lesions*, Computer Methods and Programs in Biomedicine (2022), <https://doi.org/10.1016/j.cmpb.2022.106620>

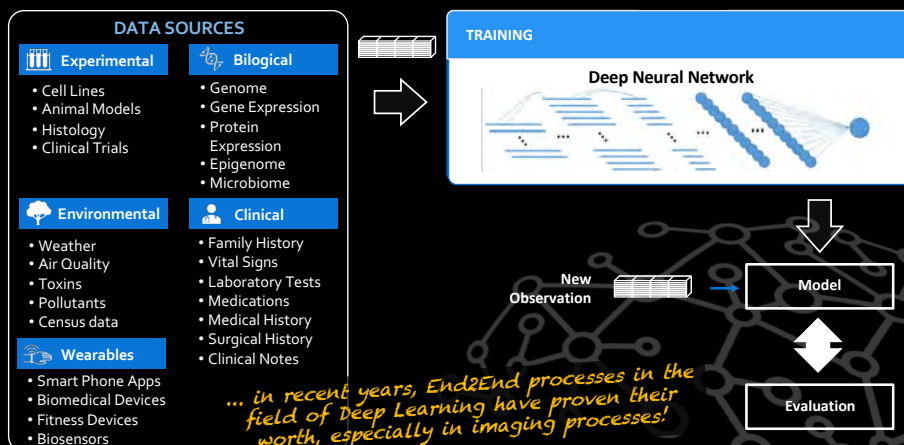
<sup>4</sup> <https://exaid.ki.dfki.de/>

Machine learning uses a lot of sample data from a wide variety of sources to make meaningful models for classifying and predicting diseases



DFKI THIRD MISSION 3

Machine learning uses a lot of sample data from a wide variety of sources to make meaningful models for classifying and predicting diseases



DFKI THIRD MISSION 4

## Take Away

### "AI for Humans"

*"The greatest potential of AI lies in its ability to act as an intellectual amplifier to identify or clarify yet unknown relationships of data and pave the way for new methods to prevent and treat disease, but we have to streamline the process of data sharing!"*



DFKI THIRD MISSION 27



## Tim Joda

# Digital implant dentistry reloaded: artificial intelligence in implant dentistry

There are now four significant digital trends and innovations in the dental field. The speaker described these as 'dental megatrends':

- **Artificial intelligence (AI):** diagnostics, visualisation, patient communication, robotics
- **Big data:** collection of eHealth data including analysis, linkage security and ethics
- **3D printing:** chairside and labside protocols; dental materials sciences
- **Ecological and social sustainability:** access to dental therapy for all population groups

The global AI health market is growing quickly and will have a significant impact on dentistry in the coming years. In 2022 the value of the market was USD 15.4 billion. The traditional implant workflow will change rapidly:

- AI-assisted **x-ray analysis** can differentiate the type of implant on an x-ray, create an automated dental chart, analyse the temporomandibular joint, quantify the airway, and identify bone pathologies, etc.<sup>1</sup>.
- **Implant planning** is already being supported by commercially available AI tools that can automatically segment teeth and the mandibular nerve and to measure the width and height of the alveolar ridge, quantifying both the hard and soft tissue<sup>2</sup>. Systems that can automatically suggest the 3D position of the implant and choice of abutment are likely to become available in the future<sup>3</sup>.
- AI-assisted **surgical implant placement**, is being developed in order to create virtual surgical processes. These can start by modelling the extraction, then calculate the emergence

profile and the gap to be filled, as well as helping to assess the primary stability of the future implant. Elsewhere, in dynamic computer-assisted implant surgery, AI combines haptic navigation with 3D tracking. Some systems include augmented reality glasses that overlay the virtual CBCT implant planning scenario on to the surgical field.<sup>4</sup>

- **Robotic-assisted implant surgery** is beginning to become a reality<sup>5</sup>. Although evidence is limited and performance is not yet optimal, a recent case series study found that haptic robotic guidance provides additional intraoperative benefits with mean and maximum deviations similar to other guided surgery techniques<sup>6</sup>. Robotic arms are capable of fine torque control, can sense the environment, can operate remotely and can be trained using human demonstration.
- In **implant prosthetics**, researchers are close to developing an AI algorithm for anatomical landmark identification for automatic maxillo-mandibular relationship registration. Several commercially available systems are now being used to simulate outcomes on a virtual patient that is created by superimposition of all the recorded data, including dynamic movements<sup>7</sup>.
- Patient treatment is moving further towards personalised implant care through **patient monitoring** to prevent peri-implant complications. One area of research is intraoral biosensors to monitor implant health<sup>8</sup>. The goal would be to have a predictive model — a digital twin — to simulate treatment while taking individual risk profiles into account<sup>9</sup>. A deep learning model combining clinical and radiographic features was recently developed. This used data from a 5-year retrospective study to predict implant loss and performed with acceptable efficiency<sup>10</sup>.

1 Urban R, Haluzová S, Strunga M, Surovková J, Lifková M, Tomášik J, Thurzo A. *AI-assisted CBCT data management in modern dental practice: benefits, limitations and innovations*. Electronics, MDPI. 2023;12(7):1710. DOI:10.3390/electronics12071710

2 Bayrakdar SK, Orhan K, Bayrakdar IS, et al. *A deep learning approach for dental implant planning in cone-beam computed tomography images*. BMC Med Imaging. 2021;21(1):86. DOI:10.1186/s12880-021-00618-z

3 Joda T, Balmer M, Jung RE, Ioannidis A. *Digital prosthetic diagnostics and digital planning: a scoping review*. Clin Oral Implants Res 2023 [submitted]

4 Joda T, Gallucci GO, Wismeijer D, Zitzmann NU. *Augmented and virtual reality in dental medicine: A systematic review*. Comput Biol Med. 2019;108:93-100. DOI:10.1016/j.combiomed.2019.03.012

5 <https://www.nyu.edu/about/news-publications/news/2022/may/dental-student-led-robot-assisted-surgery.html>

6 Bolding SL, Reebye UN. *Accuracy of haptic robotic guidance of dental implant surgery for completely edentulous arches*. J Prosthet Dent. 2022;128(4):639-47. DOI:10.1016/j.prosdent.2020.12.048

7 Joda T, Gallucci GO. *The virtual patient in dental medicine*. Clin Oral Implants Res. 2015;26(6):725-6. dOlo: 10.1111/clr.12379

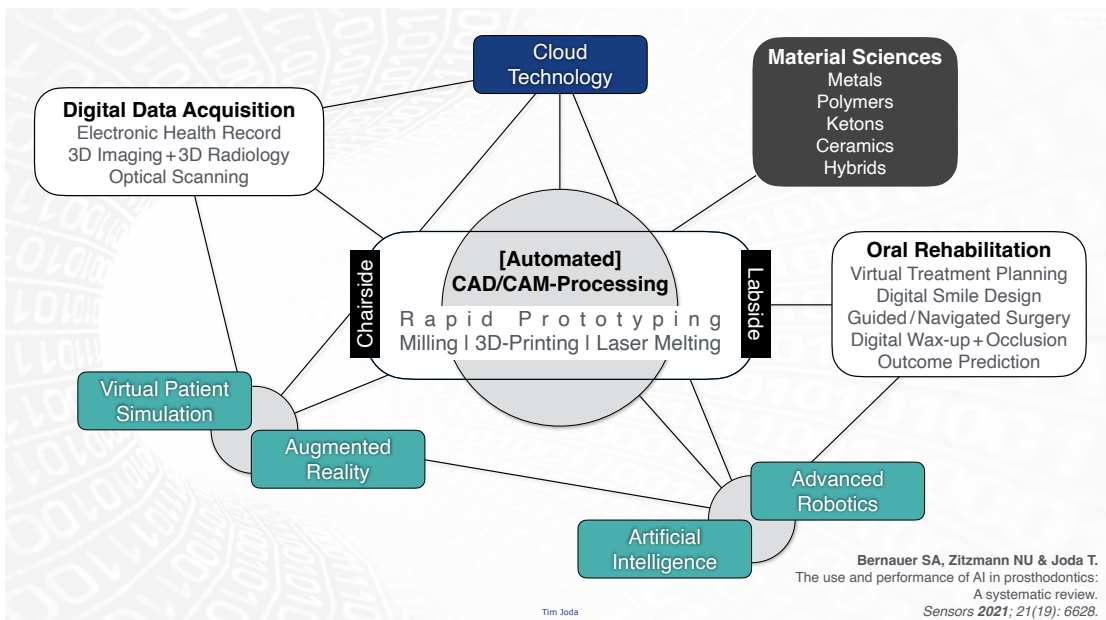
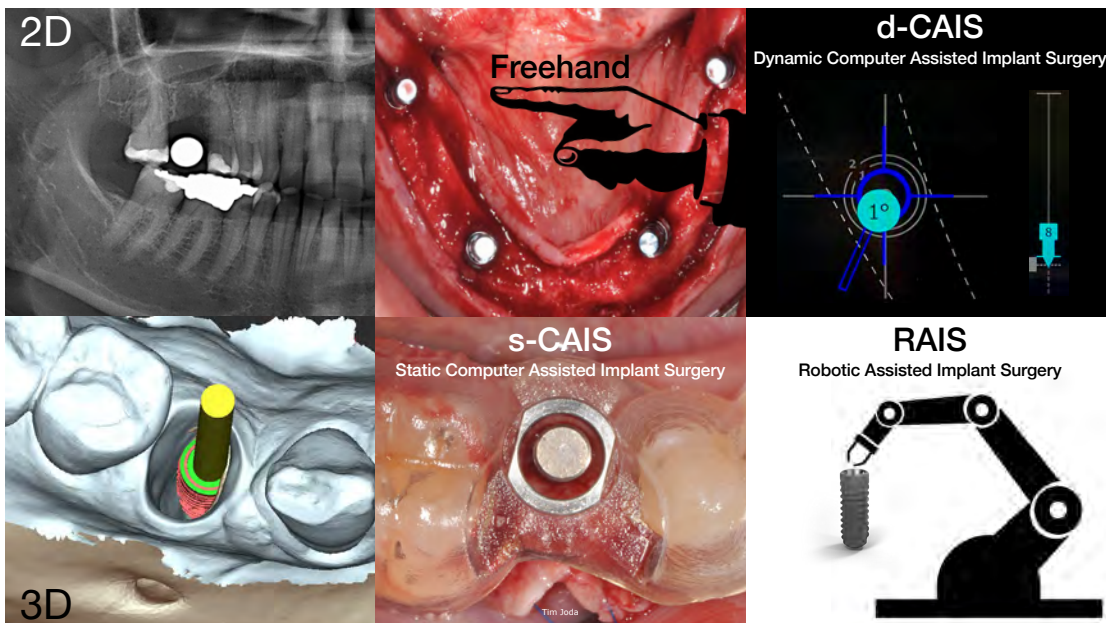
Joda T, Brägger U, Gallucci G. *Systematic literature review of digital three-dimensional superimposition techniques to create virtual dental patients*. Int J Oral Maxillofac Implants. 2015;30(2):330-7. DOI:10.11607/jomi.3852

8 Paqué PN, Hjerpe J, Zuercher AN, Jung RE, Joda T. *Salivary biomarkers as key to monitor personalized oral healthcare and precision dentistry: A scoping review*. Front Oral Health. 2022;3:1003679. DOI:10.3389/froh.2022.1003679

9 Joda T, Zitzmann NU. *Personalized workflows in reconstructive dentistry-current possibilities and future opportunities*. Clin Oral Investig. 2022;26(6):4283-90. DOI:10.1007/s00784-022-04475-0

Joda T, Waltimo T, Probst-Hensch N, Pauli-Magnus C, Zitzmann NU. *Health Data in Dentistry: An Attempt to Master the Digital Challenge*. Public Health Genomics, 2019;22(1/2), 1-7. <https://www.jstor.org/stable/26788803>

10 Huang N, Liu P, Yan Y, et al. *Predicting the risk of dental implant loss using deep learning*. J Clin Periodontol. 2022;49(9):872-83. DOI:10.1111/jcpe.13689



# Take Home Message

## AI Has the Potential to Disrupt [Implant] Dentistry

- Imaging Data Collection + Diagnostic Analysis
- Automatic Virtual Implant Planning
- Dynamic Navigation + Robotic Assisted Implant Surgery
- Remote Monitoring to Maintain Implant Health

Joda T, Yeung AWK, Hung K, Zitzmann NU & Bornstein MM.  
Disruptive innovation in dentistry: What it is and what could be next?  
*J Dent Res* 2021; 100(5): 448.

## Arjan Vissink

# Digital implant dentistry reloaded: big data in implant dentistry

### What conventional studies can and cannot reveal

The speaker began by referring to a study on what sales data tells us about implant survival. This was a 7-year retrospective study that looked at more than 93,000 implant sales. The findings were relatively unsurprising, with most implants lost early, and shorter implants more likely to be lost than longer ones. It revealed that 4.3mm diameter implants had the lowest failure rates, with a significantly higher failure rate for 6mm diameter implants, which were associated with the highest return rate<sup>1</sup>. However, this type of study does not reveal anything about factors such as the role of immediate, early or conventional implant placement; peri-implant parameters; or peri-implant health.

A second study involved a retrospective review of 27,000 implant procedures and looked at who should place implants. This found (again, unsurprisingly) that the more implants the practitioner placed, the lower the failure rate. Furthermore, early failure rates were lower for periodontists than oral surgeons<sup>2</sup>. However, no data on indications were reported, and as a result no conclusions could be drawn about factors such as those mentioned above.

Large data sets can, however, provide information about the health status of patients. In the Netherlands, for example, the health and socioeconomic status of a cohort of nearly 260,000 elderly people was assessed, and concluded that older people with natural dentition or implant overdentures had better general health than those with full dentures<sup>3</sup>. A second prospective study of 169,000 older people from the same group found that those with natural dentition had significantly better health and lower nursing home admissions compared with edentulous people (with or without dental implants). However, general healthcare costs were comparable across the two groups<sup>4</sup>. The speaker emphasised that both these studies could have provided more valuable results if they had also collected data covering other domains, such as implant type, loading and survival.

A study looking at oral health problems in community-dwelling older people found no association between malnutrition, oral health problems and edentulousness. However, health-related

quality of life was significantly associated with malnutrition, while edentulousness and oral health problems were not<sup>5</sup>. The speaker again described this study as a 'nice attempt', but noted that no data on implants was collected other than that they were used for an implant-supported overdenture.

The next study to be presented featured data on common oral health problems (for instance dry mouth and oral pain), and demonstrated differences between older people with complex care needs (who had more oral health problems) and more robust older people. When frailty progresses, the first group often needs assistance to visit the dentist<sup>6</sup>. The speaker's observations were the same as previously regarding the limitations of the study due to the lack of implant-related information.

### What can be learned from a big data approach?

The presentation then considered the placement of dental implants in patients with Sjögren's disease, which is a chronic, progressive auto-immune disease. The study that was presented<sup>7</sup> showed that implants in Sjögren's disease patients performed similarly to those in healthy patients using data collected via validated questionnaires. The medical data was all well-classified and included information on implant placement, implant health and implant survival (although there was no data on implant brand, superstructure or loading protocol).

Studies like this set the stage for an effective big data approach because the data that has been collected is structured using established criteria that are used worldwide<sup>8</sup>. In order to extract maximum knowledge from a 'big data' cohort, data should be classified according to equivalent and more detailed criteria internationally. Such classification criteria should be in place and agreed upon before reliable, clinical relevant conclusions can be drawn from big data in implant research.

The speaker then discussed the Big Data Sjögren Project, which builds on this principle by leveraging data that has been classified according to equivalent criteria internationally and combined to create a uniform data-set from all over the world<sup>9</sup>. This process can

1 Seemann R, Jirku A, Wagner F, Wutzl A. *What do sales data tell us about implant survival?* PLoS One. 2017;21(12):e0171128. DOI:10.1371/journal.pone.0171128

2 Mordechali F, Tali C, Jonathan M, Ori P, Yaron B, Ram S, Guy T. *The effect of type of specialty (periodontology/oral surgery) on early implant failure: a retrospective "Big-Data" study from a nation-wide dental chain in Israel.* Clin Oral Investig. 2022;26(10):6159-63. DOI:10.1007/s00784-022-04565-z

3 Bakker MH, Vissink A, Raghoobar GM, Visser A. *General health status of Dutch elderly receiving implant-retained overdentures: A 9-year big data cross-sectional study.* Clin Implant Dent Relat Res. 2021;23(2):228-35. DOI:10.1111/cid.12984

4 Bakker MH, Vissink A, Raghoobar GM, Peters LL, Visser A. *General health, healthcare costs and dental care use of elderly with a natural dentition, implant-retained overdenture or conventional denture: an 8-year cohort of Dutch elderly (aged 75 and over).* BMC Geriatrics 2021;21:477 DOI:10.1186/s12877-021-02427-z

5 Bakker MH, Vissink A, Spoorenberg SLW, Jager-Wittenaar H, Wynia K, Visser A. *Are Edentulousness, Oral Health Problems and Poor Health-Related Quality of Life Associated with Malnutrition in Community-Dwelling Elderly (Aged 75 Years and Over)? A Cross-Sectional Study.* Nutrients. 2018;10(12):1965. DOI:10.3390/nu10121965

6 Bakker MH, Vissink A, Spoorenberg SLW, Wynia K, Visser A. *Self-reported oral health problems and the ability to organize dental care of community-dwelling elderly aged ≥75 years.* BMC Oral Health. 2020;20(1):185. DOI:10.1186/s12903-020-01175-7

7 Korfage A, Raghoobar GM, Arends S, Meiners PM, Visser A, Kroese FG, Bootsma H, Vissink A. *Dental Implants in Patients with Sjögren's Syndrome.* Clin Implant Dent Relat Res. 2016;18(5):937-45. DOI:10.1111/cid.12376

8 Acar-Denizli N, Kostov B, Ramos-Casals M; Sjögren Big Data Consortium. *The Big Data Sjögren Consortium: a project for a new data science era.* Clin Exp Rheumatol. 2019;37 Suppl 118(3):S19-S23. PMID: 31464669.

9 Shiboski CH, Shiboski SC, Seror R, et al, and the International Sjögren's Syndrome Criteria Working Group. *2016 American College of Rheumatology/European League Against Rheumatism classification criteria for primary Sjögren's syndrome.* Ann Rheum Dis. 2017;76:9-16. DOI:10.1136/annrheumdis-2016-210571

reveal general trends, provide an insight into pathogenesis, and uncover signs of underlying disease.

The next stage for implant dentistry is to record patient and implant data in a consistent manner, to track and measure cases

uniformly, and to record placement and loading protocols. When executed properly, this approach can reveal general trends and enable aetiological factors to be deduced, leading to more targeted diagnosis and treatment.

## Discussion

### Computer or robotic assisted implant surgery (CAIS—RAIS)

In terms of the limitations of CAIS, the static approach requires a pre-planned 3D treatment that cannot be modified during its execution. It is also based on a CBCT scan that uses ionising radiation. On the other hand, with RAIS featuring haptic navigation, the operator has the freedom to adapt to the surgical field; however, without augmented reality glasses, the operator must work while looking at the monitor. Also, while a trained surgeon can place an implant with 'brain-guided freehand' to within a millimetre of accuracy, the first RAIS case series showed maximum deviations of up to 4mm. We must be cautious in the early adoption of these new technologies.

### Quality of data

Even though source data may have quite diverse characteristics, AI systems can now highlight the data that is required for decision-making. Based on this process, abnormal aspects or outliers can also be identified and data can be properly balanced. It is possible to study different subjects at the same time and balance samples of different cases.

In terms of image analysis, AI systems use a 'scent box' of around 40 to 60 topologies of the object in order to recognise it.

In conventional studies, it is common to draw false conclusions by partially ignoring some aspects of the data. Now, however, all data

from all patients, including multiple characteristics and treatment records, can be unified and processed.

### AI predicted risks

Any AI-generated risk prediction can be discussed with the patient and an informed decision can be made. However, AI may lead to previously unforeseen problems. For instance, insurance companies may refuse implant treatment if an AI system indicates it is high-risk. In effect, AI is changing the way healthcare is delivered.

### Classification

In response to the question "Should we move from static categories to dynamic AI classifications?", the speaker responded by saying that the complexity of the body makes it impractical to provide individualised treatments in every area and for every treatment. However, it will potentially be possible to classify people into some main categories (such as age and nutrition) and start to adapt the treatment.

### Data security

Using AI to process large data sets allows deep correlations and dependencies to be revealed, and it is logical to be hesitant about the privacy of metadata. However, this is partly a question of attitude, and younger generations seem to be more open to data sharing, although there are also differences in national cultures and legal systems. A reasonable approach would be to have the ability to decide what kind of data to share, for what period of time, and for what purpose. But this has yet to be achieved.



# Battle of concepts: surgical treatment of peri-implantitis

This session took the form of a debate that focused on different treatment concepts for peri-implantitis. Rather than being a battle, the presentations were complementary.

According to a recent World Workshop<sup>1</sup>, peri-implantitis can be diagnosed when there is bleeding or suppuration on gentle probing, pocket depth (PD) is  $\geq 6$  mm; and marginal bone loss (MBL) is  $\geq 3$  mm.

The session explored a range of issues, including:

- When to opt for regenerative or resective surgery
- Whether the prosthesis should be modified or the tissue augmented
- How to handle a peri-implantitis patient with advanced periodontitis
- When to explant a diseased implant

## Ausra Ramanauskaite

### Peri-implantitis treatment: a stepwise approach

A stepwise treatment approach involves addressing local factors that contribute to the disease's onset. It is well known that patients who are non-compliant with a maintenance programme or have a history of periodontitis are predisposed to peri-implantitis. The goal of the non-surgical phase should be to help patients achieve and maintain adequate oral hygiene, and to ensure that if periodontitis is present it is under control<sup>2</sup>. Furthermore, prosthesis that is over-contoured and impairs access to oral hygiene procedures should be modified before proceeding to the primary treatment<sup>3</sup>.

Although a range of adjunctive measures can be added to the non-surgical phase, the core approach continues to be submarginal instrumentation, whether carried out using curettes or sonic/ultrasonic devices<sup>4</sup>. The goal is to resolve the inflammation in the soft tissue compartment, with the ideal outcome of the non-surgical phase being that there is no suppuration, PD is  $\leq 5$  mm and there is  $\leq 1$  point of BOP<sup>5</sup>. However, after four to eight weeks, most patients do not reach these parameters and should undergo surgery.

A recent meta-analysis<sup>6</sup> showed that when the width of the keratinised tissue (KT) is below 2 mm, the consequences are increased prevalence of peri-implantitis, plaque accumulation,

soft tissue inflammation, mucosal recession, marginal bone loss and patient discomfort. A commercially available tissue substitute was compared with a free gingival graft (FGG) as a means of augmenting KT. At six months, the study showed that both treatment approaches were viable. Although the FGG showed greater augmentation of KT, adequate results (2 mm) could be achieved with the soft tissue substitute with less patient morbidity<sup>7</sup>. This type of augmentation, if required, should be considered prior to surgical treatment.

There are four options for the surgical phase<sup>8</sup>: non-reconstructive, resective, reconstructive or combined surgery. The first step is to raise a full-thickness flap to gain adequate access to the whole defect. However, the critical stage is implant surface decontamination, since removing the biofilm is mandatory in order to resolve inflammation. There are multiple options for removing the biofilm, with no significant differences demonstrated between the majority of them, although titanium brushes have been shown to perform slightly better<sup>9</sup>. When implant surfaces are extensively exposed in a non-containing defect, the clinical data supports an implantoplasty to eliminate the threads and smooth the titanium surface in order to hinder plaque accumulation. This has been

<sup>1</sup> Caton JG, et al. *A new classification scheme for periodontal and peri-implant diseases and conditions – Introduction and key changes from the 1999 classification*. J Clin Periodontol. 2018;45:S1-S8. DOI:10.1111/jcpe.12935

<sup>2</sup> Herrera D, *Prevention and treatment of peri-implant diseases-The EFP S3 level clinical practice guideline*. J Clin Periodontol. 2023;50 Suppl 26:4-76. DOI: 10.1111/jcpe.13823

<sup>3</sup> Schwarz F, et al. *Peri-implantitis: Summary and consensus statements of group 3. The 6th EAO Consensus Conference 2021*. Clin Oral Implants Res. 2021;32:245-53. DOI:10.1111/clr.13827

<sup>4</sup> Herrera et al, 2023 opus cit.

<sup>5</sup> Herrera et al, 2023 opus cit.

<sup>6</sup> Ramanauskaite A, Schwarz F, Sader R. *Influence of width of keratinized tissue on the prevalence of peri-implant diseases: A systematic review and meta-analysis*. Clin Oral Implants Res. 2022;33 Suppl 23:8-31. DOI:10.1111/clr.13766.

<sup>7</sup> Ramanauskaite A et al. *Three-dimensional changes of a porcine collagen matrix and free gingival grafts for soft tissue augmentation to increase the width of keratinized tissue around dental implants: a randomized controlled clinical study*. Int J Implant Dent. 2023;16;9(1):13. DOI: 10.1186/s40729-023-00482-2

<sup>8</sup> Schwarz F, Jepsen S, Obreja K, Galaraga-Vinueza ME, Ramanauskaite A. *Surgical therapy of peri-implantitis*. Periodontol 2000. 2022;88(1):145-81. DOI:10.1111/prd.12417. PMID: 35103328

<sup>9</sup> Ramanauskaite A, Schwarz F, Cafferata EA, Sahrman P. *Photo/mechanical and physical implant surface decontamination approaches in conjunction with surgical peri-implantitis treatment: A systematic review*. J Clin Periodontol. 2023;50 Suppl 26:317-35. DOI:10.1111/jcpe.13783

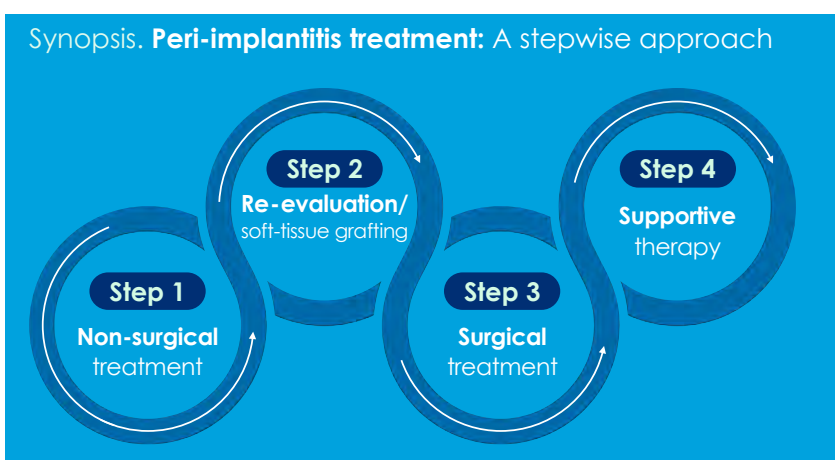
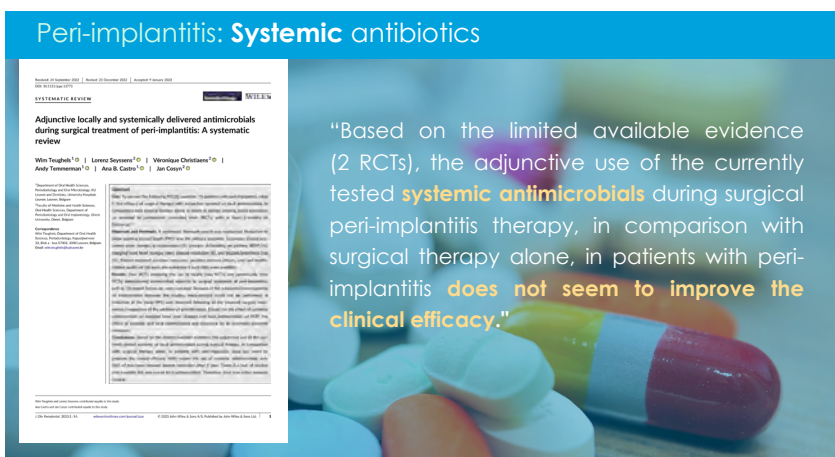
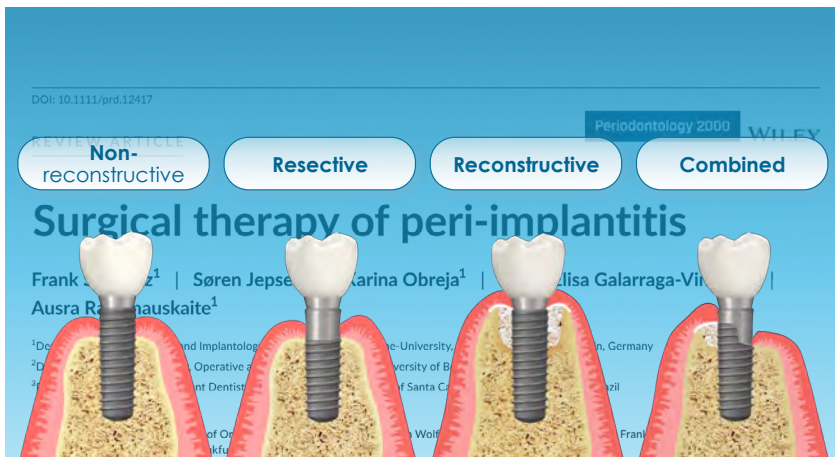


shown to lead to a significant reduction in PD<sup>10</sup>. Following the decontamination phase, a decision has to be made on which surgical approach to follow. As an aside, a recent systematic review suggested that the use of antibiotics as an adjunct to surgical procedures does not improve the clinical efficacy, although the evidence available was limited<sup>11</sup>.

The outcome after six months should be the resolution of the inflammation, accompanied by no clinical signs of disease, shallow

PD and no progression of MBL. However, the patient should receive supportive therapy every 3–4 months for the first year after treatment, followed by appropriate individualised treatment, based on their risk profile, beyond that<sup>12</sup>.

The take-home message was that surgical procedures should only be performed after risk factors have been controlled and the non-surgical phase is complete.



<sup>10</sup> Ramanauskaitė A, Fretwurst T, Schwarz F. Efficacy of alternative or adjunctive measures to conventional non-surgical and surgical treatment of peri-implant mucositis and peri-implantitis: a systematic review and meta-analysis. *Int J Implant Dent.* 2021;15:7(1):112. DOI:10.1186/s40729-021-00388-x

<sup>11</sup> Teughels W, Seys L, Christiaens V, Temmerman A, Castro AB, Cosyn J. Adjunctive locally and systemically delivered antimicrobials during surgical treatment of peri-implantitis: A systematic review. *J Clin Periodontol.* 2023;50 Suppl 26:359-72. DOI:10.1111/jcpe.13773

<sup>12</sup> Herrera et al, 2023 opus cit.

## Lisa Heitz-Mayfield

### Reconstruction of peri-implantitis defects. The why, when and how ... in 15 minutes

The speaker focused on why, when and how to reconstruct peri-implantitis defects<sup>1</sup>.

The main objective of peri-implantitis treatment is to resolve inflammation and establish peri-implant tissue health. The reconstructive approach has two additional goals: regenerating bone and minimising soft tissue recession.

#### When should the approach be reconstructive?

A reassessment following the non-surgical phase is the right time to decide which surgical approach to take. Patients must be periodontally healthy, have no medical contraindications, ideally be non-smokers and be willing to follow a maintenance programme. The site-related factors are whether the defect configuration is suitable<sup>2</sup> (a 3- or 4-wall contained intraosseous defect with  $\geq 3$ mm depth) and whether KT is present, as there is now evidence that it can prevent inflammation and facilitate flap handling. In addition, the prosthesis should be easy to clean and the implant should be in the correct position<sup>3</sup>.

#### How should the reconstructive approach be performed?

The flap design should provide adequate access in order to remove the granulation tissue, decontaminate the implant surface and graft

the defect. Sufficient flap adaptation and post-operative care are also necessary. A recent RCT study compared access flap surgery with a xenograft covered by a collagen membrane. The trial showed similar good clinical and radiographic improvements for both groups at 12 months. In this study, patient satisfaction was also included in the success criteria. A visual analogue scale (VAS) was used to record pain during surgery, pain the first week after surgery, and appearance at 12 months. Patient satisfaction levels were high for both approaches<sup>4</sup>.

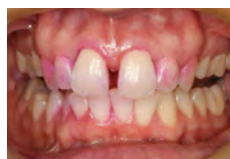The speaker's conclusions were as follows:

- when attempting reconstructive therapy, the conditions must be ideal
- patients must be chosen very carefully
- the implant position and prosthesis must also be evaluated very carefully
- the defect morphology needs to be the right type
- the surgical procedure and materials must be sufficiently well documented
- the post-operative care protocol must be meticulously followed for a successful outcome

### Reconstructive treatment- WHEN

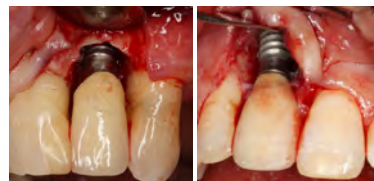
#### Patient related factors

Low FMPS/FMBS < 20%  
Smoking < 10 cigarettes/day  
No medical contraindications  
Participation in supportive care program



#### Site related factors

Intraosseous defect  
3- or 4-wall contained defect  
minimum 3 mm depth  
presence of keratinised peri-implant mucosa



Regeneration of alveolar ridge defects. Consensus report of group 4 of the 15th European Workshop on Periodontology on bone regeneration. Jepsen et al. 2019 | J Clin Periodontol

Impact of defect configuration on the clinical outcome following surgical regenerative therapy. Schwarz et al. 2010 | J Clin Periodontol

<sup>1</sup> ITI Treatment Guide Volume 13. *Prevention and Management of Peri-Implant Diseases*. Lisa J. A. Heitz-Mayfield & Giovanni E. Salvi, 2022, Quintessence Int.

<sup>2</sup> Schwarz F, Sahm N, Schwarz K, Becker J. *Impact of defect configuration on the clinical outcome following surgical regenerative therapy of peri-implantitis*. J Clin Periodontol. 2010;37(5):449-55. DOI:10.1111/j.1600-051X.2010.01540.x

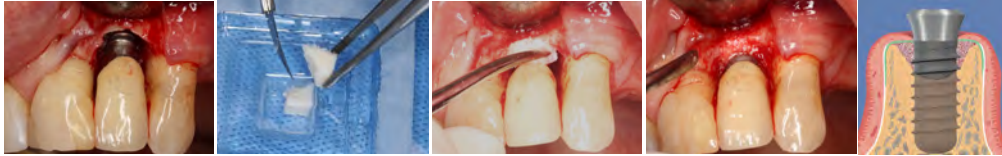<sup>3</sup> Jepsen S, et al. *Regeneration of alveolar ridge defects. Consensus report of group 4 of the 15th European Workshop on Periodontology on Bone Regeneration*. J Clin Periodontol. 2019;46 Suppl 21:277-86. DOI:10.1111/jcpe.13121

<sup>4</sup> Heitz-Mayfield L, Heitz F, Koong B, Huang T, Chivers P. *Surgical peri-implantitis treatment with and without guided bone regeneration. A randomized controlled trial*. Clin Oral Implant Res. 2023;34(9):892-910.DOI:10.1111/clr.14116

## Reconstructive treatment- HOW

**Flap design** for adequate access to the defect and adequate coverage and stability of the graft material

- Removal of inflamed tissue
- **Decontamination** of the implant surface
- Placement of the **graft** material (with or without a barrier membrane)
- Adequate flap adaptation
- Adequate **post-operative care** including a post-operative period of use of chlorhexidine



Regeneration of alveolar ridge defects. Consensus report of group 4 of the 15th European Workshop on Periodontology on bone regeneration **Jepsen et al. 2019 | J Clin Periodontol**

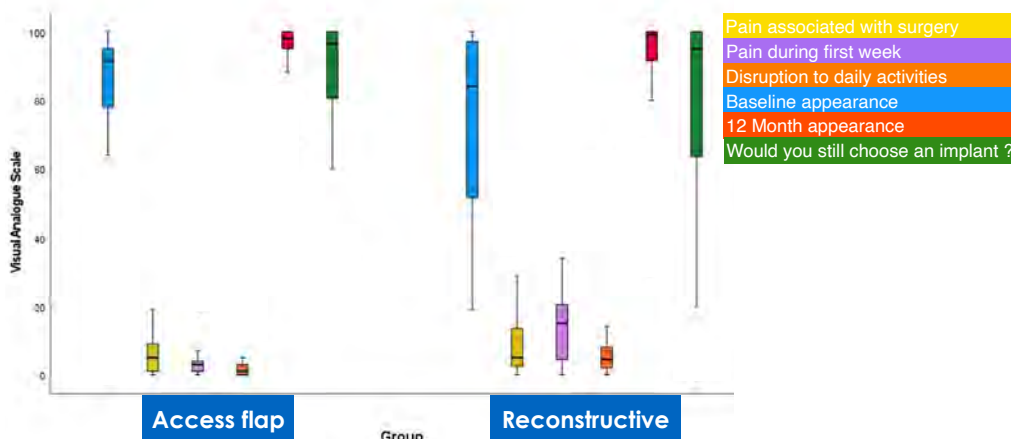
Surgical peri-implantitis treatment with and without guided bone regeneration. An RCT  
Heitz-Mayfield L, Heitz F, Koong B, Huang T, Chivers P **COIR 2023**

Reference study	Success Criteria Composite Outcome	Control N=20 Access flap F (%)	Test N=20 Reconstructive F (%)	Total N = 40 F (%)
Heitz-Mayfield et al. 2018 Case series	Absence of PD $\geq$ 5 mm with BOP Absence of suppuration Absence of progressive bone loss	18 (90%)	17 (85%)	35 (87.5%)
Jepsen et al. 2016 RCT	PD $\leq$ 4 mm Absence of BOP Absence of suppuration Absence of progressive bone loss	11 (55%)	12 (60%)	23 (57.5%)
Renvert et al. 2018 RCT	PD $\leq$ 5 mm Absence of BOP Absence of suppuration Defect fill $\geq$ 1 mm (bone fill)	8 (40%)	11 (55%)	19 (47.5%)
Derks et al. 2022 Regidor et al. 2023 RCTs	PD $\leq$ 5 mm Absence of BOP Absence of suppuration $\leq$ 1 mm recession of buccal mucosa	9 (45%)	10 (50%)	19 (47.5%)
Heitz-Mayfield et al. 2023 <b>Novel criteria:</b> including patient reported outcome appearance	PD $\leq$ 4 mm Absence of BOP Absence of suppuration Increase in bone level of $\geq$ 1 mm Buccal mucosal recession $\leq$ 1 mm OR patient satisfaction with appearance	7(35%)	10 (50%)	17 (42.5%)

Heitz-Mayfield et al. 2023 COIR

Surgical peri-implantitis treatment with and without guided bone regeneration. An RCT  
Heitz-Mayfield L, Heitz F, Koong B, Huang T, Chivers P **COIR 2023**

### Patient Reported Outcomes - VAS scores



## Alberto Monje

### Resective therapy for peri-implantitis

The speaker provided a rationale for resective therapy for peri-implantitis using a stepwise approach. Surgical therapy aims to change the environment from anaerobic to aerobic, and hence to create a situation that is more compatible with peri-implant health. Clinically, this means reducing the depth of the pockets, which can be achieved by flattening the bone architecture and repositioning the flap apically, similar to the classical treatment of periodontitis. Resective therapy is indicated for defects that are unable to retain the blood clot.

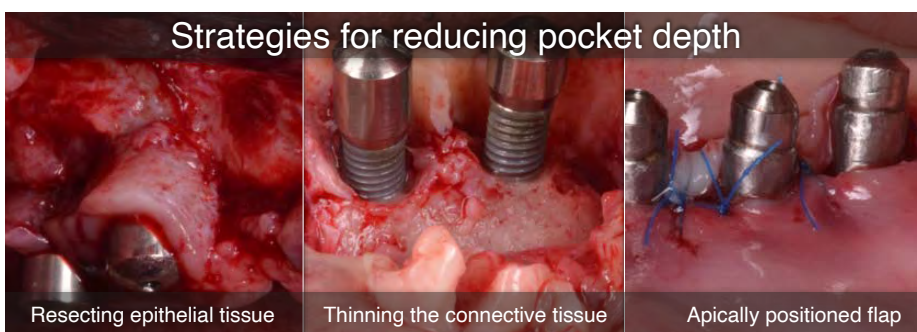
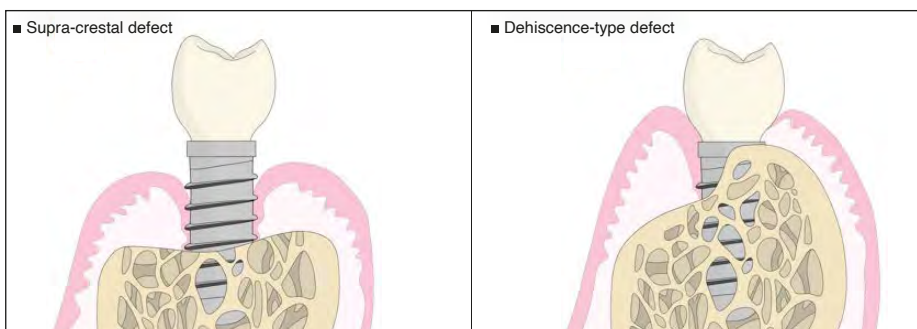
There are two types of unconfined defects: supra-crestal defects, which are initially circumferential in shape and evolve to a horizontal bone loss pattern; and dehiscence-type defects, which often occur outside the bone envelope due to buccal remodelling.

Strategies for reducing pocket depth include: epithelial tissue resection when there is enough KT; connective tissue thinning when the KT band is insufficient; and an apically positioned flap closed with a vertical mattress suture. Together with osteoplasty, implantoplasty may be recommended to make the implant

surface less friendly to plaque. Of course, confounder factors, like prosthesis design, must be controlled as soon as possible.

In most cohorts, the effectiveness of resective therapy results in an implant survival rate of 95%, while the rate of disease resolution rate is over 65%, slightly higher than for the reconstructive approach. Indicators for recurrence include patient-related factors such as smoking or lack of hygiene compliance, implant-related factors such as modified surfaces and local factors such as an insufficient KT band. To address the latter, resective therapy can be modified to include the required soft tissue conditioning procedures. Thus, a crestal full-thickness crestal flap is followed by a split-thickness flap on the buccal aspect to stabilise an FGG that is used to increase the vestibular depth. Needless to say, the avascular implant surface should not be covered by the graft, which should be stabilised apically over the vascular bed.

The speaker concluded by noting that a failure to enhance the patient's oral hygiene or modify their risk profile will lead to peri-implantitis recurring endlessly.



#### Concluding remarks

- The therapeutic modality relies on **defect configuration**
- **Resective** therapy is effective to arrest disease
- Soft tissue **conditioning** is key to manage the disease
- Success finally relies upon **oral hygiene** and **habits**

dr.alberto\_monje

WWW.quintpub.com

amonjec@umich.edu

www.clinicacom.com



# Discussion

## Implant surface decontamination

Although the release of titanium particles is a concern when carrying out an implantoplasty, the procedure does lead to (slightly) improved clinical outcomes. Machined surfaces do not require implantoplasty but modified surfaces do. In a 4-wall defect, mechanical decontamination of the surface is really challenging and the point is to do our best.

## Risk factors

The speakers were asked how to manage risk factors in a patient who is a smoker. The advice of Ausra Ramanauskaite was that while control of risk factors is mandatory, the point is to make patients aware of them and help them understand that they are responsible for their habits. In other words, a patient who smokes can still receive treatment, but must be aware of the risks. Turning to the prosthesis, it was observed that to obtain adequate access for surgery, it is often beneficial to remove it, assuming it is possible to do so. In some cases, and if the patient is amenable, it's helpful for the prosthesis to remain absent for the first month following surgery. Sometimes removal of the prosthesis can also provide an opportunity to make a beneficial modification.

## Keratinised tissue and FGGs

KT should be attached to the periostium and 70% of the inner surface of an FGG should be in close contact with its recipient vascular bed. The decision on whether to use an FGG or a collagen matrix should be based on the amount of residual KT. Both

techniques achieve an acceptable outcome, but as the collagen matrix cannot promote keratinisation, it only should be used when a residual band of KT is present. In cases where KT is completely absent, it is better to go for an FGG.

## The reconstructive approach

The reconstructive approach demonstrated slightly more discomfort (the difference was significant) in the first week postoperatively, although it was unclear if side-effects relating to systemic antibiotics influenced this. Membranes do not seem to be necessary and may depend on defect configuration. To prevent membrane exposures, overfilling should be avoided.

## Conditions for explantation

When thinking about conditions under which a diseased implant should be explanted, aside from absolute indications (mobility, pain, fracture), it is not possible to set criteria that would be valid for all cases, since each situation must be assessed individually with the patient participating in the decision. However, circumstances when explantation may be relevant include:

- when more of 50% of the implant surface is exposed
- when the implant is in the aesthetic zone
- when the patient is unwilling to collaborate in controlling the local and systemic confounding factors
- in cases of biomechanical expendability of a particular implant



# Interdisciplinary management of complex cases reloaded

This session focused on an interdisciplinary approach to treatment planning, starting with a visualisation of the desired aesthetic end-point. It described the benefits of planning 'from the outside in' when combined with the expertise of an interdisciplinary. Excellent communication between specialists is a crucial factor in identifying the best options to address the patient's needs and optimising the final treatment outcome.

While many cases in daily practice involve several specialists, an interdisciplinary planning protocol maximises the benefits that an expert team can bring, and helps deliver the best treatment outcomes.

**Gregg Kinzer**, Prosthodontics; **Vince Kokich Jr.**, Orthodontics; **Jim Janakievski**, Periodontics

This session describes a collaborative, linear and seamless interdisciplinary approach that can be adapted to any clinical case, no matter how challenging. It involves planning all cases in the same order and following the plan step-by-step to the end. After explaining the rationale behind the approach, several cases were presented, with explanation of the steps that were taken to deliver the treatment plan that had been prepared beforehand.

Collaborative practice, as described by the speakers, is a dynamic, ongoing process that allows clinicians to blend their talents and leads to greater professional satisfaction. Two of the greatest advantages of collaborative practice are its ability to educate patients and, more importantly, for clinicians to learn from each other (gaining better understanding of other specialities) in order to improve patient care outcomes.

Traditionally, treatment planning begins with data collection: for example, obtaining study casts or digital scans, then progressing to mounting casts for functional design. Establishing this functional design has always been the first treatment step. However, the protocol described by the speakers starts with an assessment of the patient's face. To establish a basis for where to reposition the teeth, especially in cases of significant loss of vertical dimension (e.g. tooth wear), they use Dr Frank Spear's concept of 'facially generated treatment planning' which treatment plans from the outside in. Before figuring out the occlusion they plan where to place the teeth and tissues aesthetically, using the patient's face. Having done that they create a functional design and finalise the rest of the treatment plan around the facially driven tooth position.

The speakers described how they follow a sequence of four steps for all patients and all treatment plans, namely *Esthetics, Function, Structure and Biology (EFSB)*.

The steps are as follows:

1. **Aesthetics treatment planning:** teeth and tissue positioning. Where do we want things to be aesthetically (tooth position, gingival levels, contour/arrangement) on both the upper and lower arches?

2. **Functional treatment planning:** how to make the occlusion work, condylar position, muscles, vertical dimension, and the anterior relationship.
3. **Structural treatment planning:** the type of restoration (how to prepare teeth, what materials to use), the method for replacing missing teeth.
4. **Biological treatment planning:** endodontics, periodontics, and oral surgery.

A modification to this sequence was recently introduced to include another parameter: the airway. Now, before determining the position of the maxillary central incisors, the anteroposterior position and the transverse dimension of the maxilla is assessed and taken into account. The approach is similar to making a denture, in which the maxillary central incisors are first placed to mark the treatment planning position, before the laterals and canines are placed. However, in practice the very first stage of making a denture is the wax rim, which must be modified to provide lip support and arch shape before setting the teeth. The anteroposterior and transversal dimension of the wax rim is the airway element. Reflecting this, the team added the 'airway' treatment planning step as this impacts both the aesthetics and function of the patient. It involves calculating the desired dentoalveolar and skeletal positions, as these influence all other aspects of the treatment plan. In terms of the steps outlined above, this new step is stage 0.

After treatment planning the aesthetic maxillary tooth and tissue position, the position of the lower arch is then considered., followed by treatment planning function. In the mandible, the team also starts with the anterior teeth and their relationship to the face before going on to define the function. The relationship between the palatal contour of the maxillary anteriors and the incisal edge position of the mandibular anteriors will determine the new vertical, overbite, overjet.

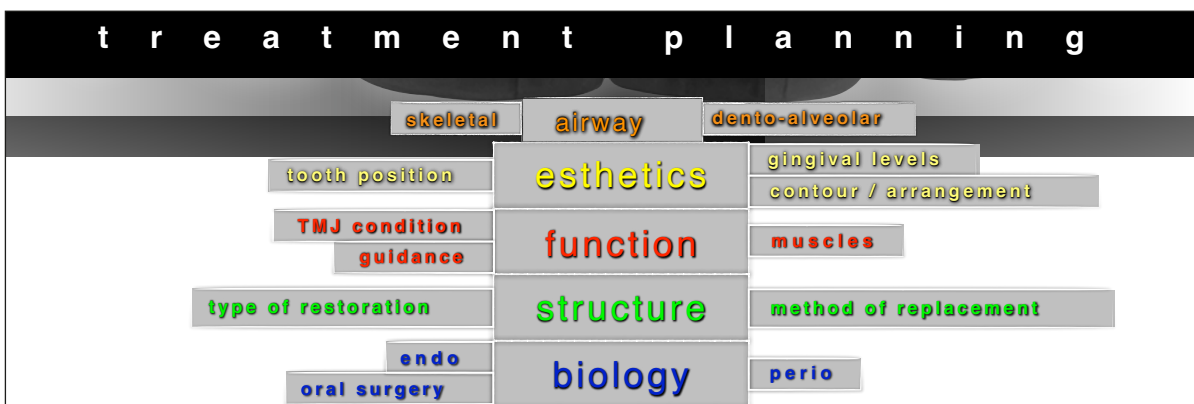
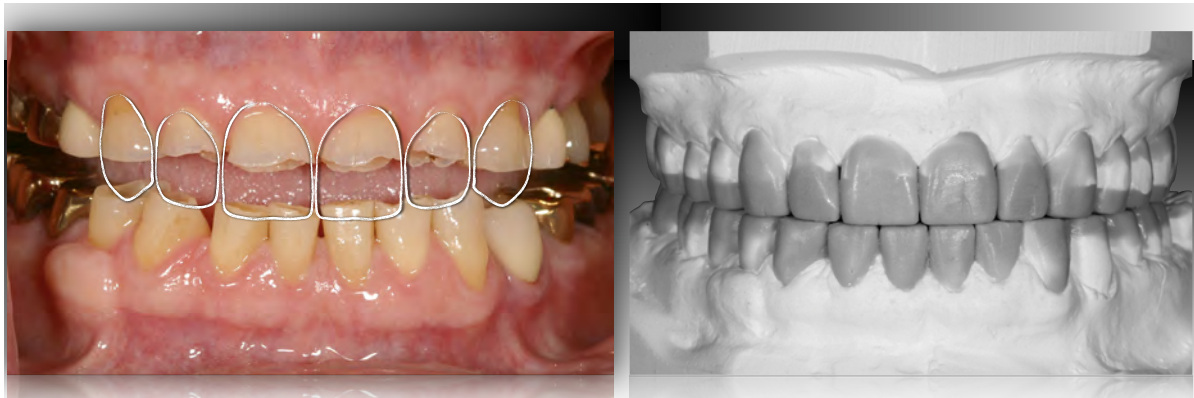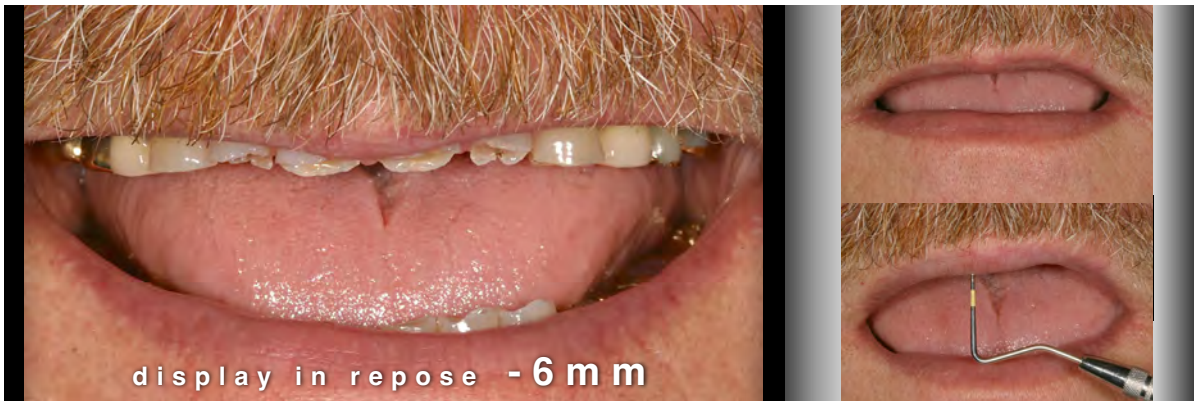When using the EFSB protocol, treatment planning is linear and very systematised. All the patients are evaluated in the same way. However, the sequence in which case is treated is a separate process that is determined after the treatment plan has been drawn up. When determining this process all the specialities (restorative, surgical, orthodontics) are involved and interconnected.

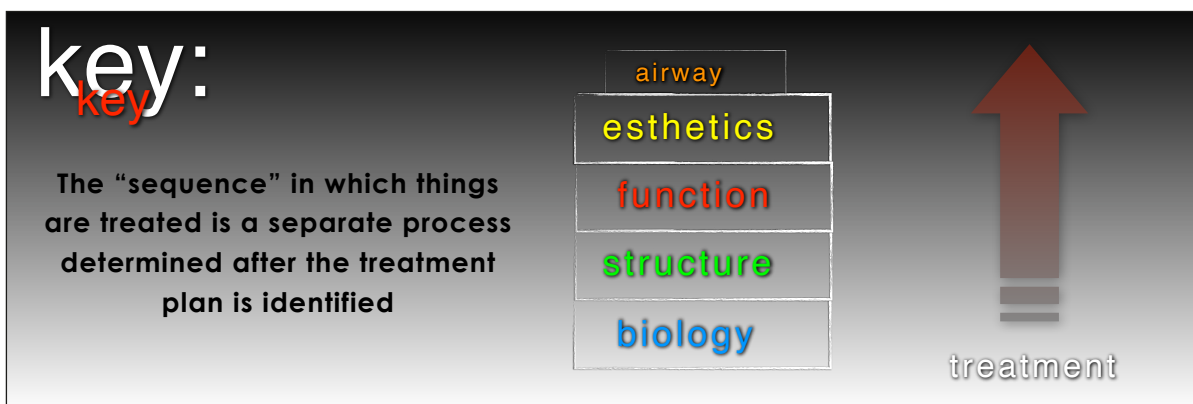
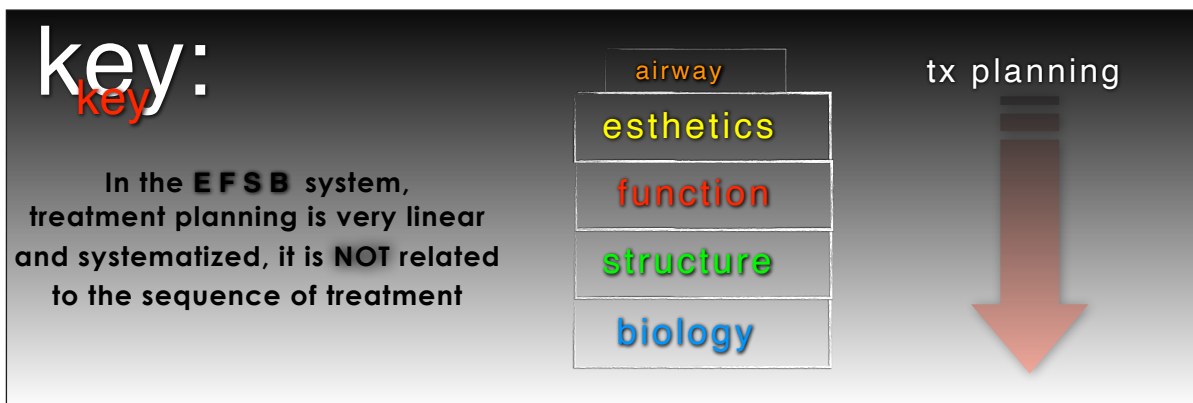
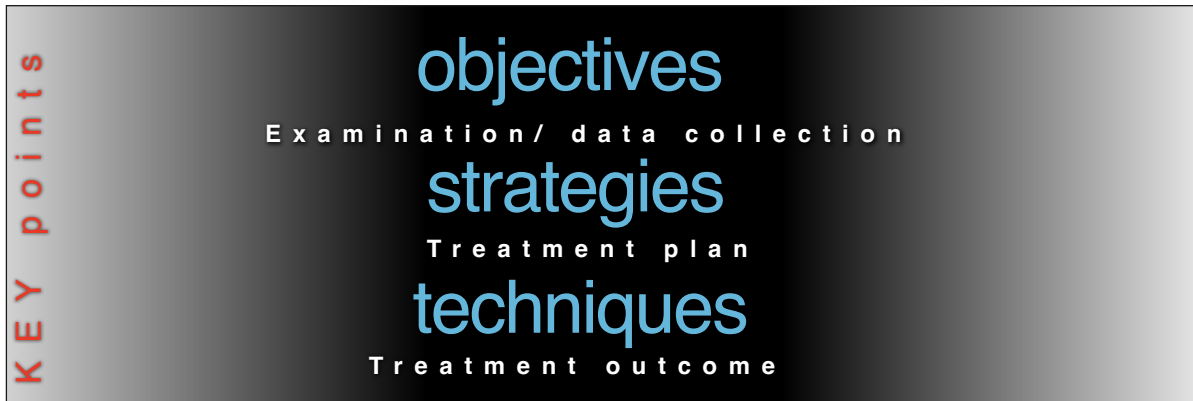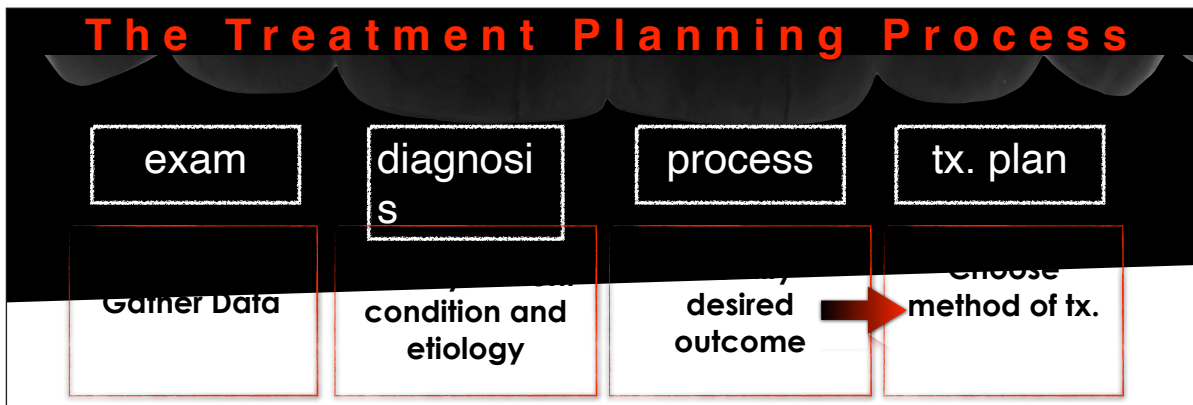
As with conventional treatment planning, the protocol described by the speakers begins with an examination, data collection and diagnosis (identifying the current condition and aetiology). However, conventional planning then jumps straight to the treatment plan, missing out the 'process' stage. The speakers argued that it is a mistake to omit this 'ideal first step', which involves identifying the desired final outcome to be achieved. Before establishing what needs to be done (the treatment plan), it is critical to know what the aim is and where the teeth, tissue and the occlusion must be positioned.

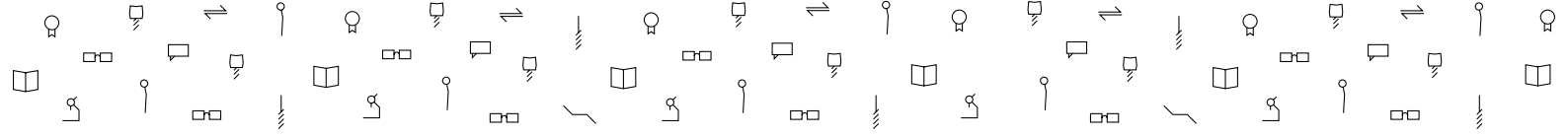
When preparing a case, it is essential to think about the objectives and the desired outcomes before turning to the strategies and techniques that will be used to achieve these outcomes.

1. **Objectives.** Listen to the patient. and identifying what their expectations are. What are the goals of the treatment and what do the clinicians think is possible?
2. **Strategies.** Develop a treatment plan. Initiate the treatment sequence and maintain clear and open communication between team-members (the strategy may change if a new factor comes to light during treatment).
3. **Techniques.** How will the treatment be performed? What skills and abilities are required, and what materials and technologies will be selected?

Several cases where the protocol had been applied were presented by the speakers.







## European Association for Osseointegration (EAO)

**Phone:** +33 1 42 36 62 20

**Email:** [info@eao.org](mailto:info@eao.org)

**Web:** [www.eao.org](http://www.eao.org)



European Association for Osseointegration



[europeanassociationforosseointegration](https://www.facebook.com/europeanassociationforosseointegration)



[eao\\_association](https://twitter.com/eao_association)



[EAO\\_Association](https://www.youtube.com/EAO_Association)



[eao\\_association](https://www.instagram.com/eao_association)